

# 34

## Scapulectomy

Martin Malawer, James C. Wittig and Cynthia K. Rubert

---

### OVERVIEW

The scapula is a relatively common site for primary bone sarcomas, including chondrosarcoma and renal-cell carcinoma in adults and Ewing's sarcoma in children. Soft-tissue sarcomas may involve the suprascapular region or infraspinatus muscle and may secondarily invade the scapula. Tumors arising from the scapula are often initially contained by muscle, thereby protecting other tissues. Important anatomic areas to evaluate for tumor extension are the chest wall, axillary vessels, proximal humerus, glenohumeral joint, and rotator cuff.

Shoulder motion and strength are nearly normal following a partial scapular resection (Type II). However, there is significant loss of shoulder motion, predominantly shoulder abduction, following a total scapular resection (Type III), alone or in conjunction with an extra-articular resection of the shoulder joint and proximal humerus (Types IV and VI). Suspension of the proximal humerus and meticulous soft-tissue reconstruction are the keys to providing shoulder stability and a functional extremity. If significant periscapular muscles remain following tumor resection (especially the trapezius and deltoid muscles), a total shoulder-scapula prosthesis may be the optimal reconstructive option.

This chapter discusses the anatomic and surgical considerations of limb-sparing scapular resections and describes the techniques of resection and reconstruction. Additional information regarding the indications and contraindications of limb-sparing resection, surgical staging and classification, endoprosthetic reconstruction and design features, and functional and rehabilitation considerations may be found in Chapter 9.

## INTRODUCTION

Tumors arising from the scapula may become quite large before they are diagnosed (Figure 34.1). Initially, they are often contained by muscle, thereby protecting other tissues. They often present with pain, a mass, or both. Chondrosarcomas are the most common primary malignancy of the scapula in adults; in children the most common primary malignancy of the scapula is Ewing's sarcoma (Figures 34.2 and 34.3). Soft-tissue tumors may involve the periscapular musculature and secondarily invade the scapula.

The first limb-sparing attempts involved tumors of the scapula. The first description of a scapular resection was published by Liston in 1820 and involved an ossified aneurysmal tumor.<sup>1</sup> Syme<sup>2</sup> performed a near-total scapulectomy with resection of the clavicle in 1856. In 1909 De Nancrede<sup>3</sup> concluded that all shoulder girdle tumors should be treated with a forequarter amputation. Since De Nancrede's paper, several authors have described modifications of scapular resections and different indications.

Today, the majority of malignancies of the shoulder girdle can be treated safely with limb-sparing surgeries. Indications for limb-sparing surgeries at this location include most high-grade bone sarcomas and some soft-tissue sarcomas, depending on the tumor extent. Scapular tumors, like tumors of the proximal humerus, require careful preoperative staging, appropriate imaging studies, and a thorough knowledge of local anatomy. Selection of patients whose tumor does not involve the neurovascular bundle, thoracic outlet, or adjacent chest wall is required. Forequarter amputation is indicated mainly for patients with large, fungating tumors, or infected tumors; those in whom limb-sparing resection has failed; and those with tumors invading the major nerves and vessels or chest wall.

A classification system for resection of tumors of the scapula and shoulder girdle is described in Chapter 9. The most common resection for a high-grade tumor of the scapula, a Type IV-B (true Tikhoff-Linberg), is illustrated in this chapter.

As with other types of shoulder girdle resections, optimal function is achieved by local muscle transfers and skeletal reconstruction. A total scapular prosthesis may be used if adequate soft tissues remain. A stable shoulder girdle that allows positioning of the elbow and hand for functional activities is the goal of shoulder girdle reconstruction.

## UNIQUE ANATOMIC CONSIDERATIONS

A limb-sparing procedure involving the shoulder girdle is more difficult than a forequarter amputation. The

surgical options are technically demanding and fraught with potential complications. The local anatomy of the tumor often determines the extent of the required operation. One should be experienced with all aspects of shoulder girdle anatomy and the unique considerations presented, which are as follows.

### Scapula

Tumors of the scapula often become quite large before being brought to a physician's attention. In the early stages of development they are surrounded by a cuff of muscle in all dimensions (infraspinatus, subscapularis, and supraspinatus). Important areas to evaluate are the chest wall, axillary vessels, proximal humerus and rotator cuff, and pericapsular tissue.

### Glenohumeral Joint

Sarcomas involving the glenoid, scapular neck, or supraspinatus area usually involve the joint and adjacent capsule. Therefore, an extra-articular resection through a combined anterior and posterior approach (see Surgical Techniques section) should be performed for tumors in this location.

### Neurovascular Involvement

As sarcomas of the scapula enlarge, they may produce a large axillary and/or anterior component and involve the axillary vessels and brachial plexus. When there is a large anterior extraosseous mass, anterior exploration of the neurovascular bundle should be performed to determine resectability or facilitate an extra-articular resection safely.

### Lymph Nodes

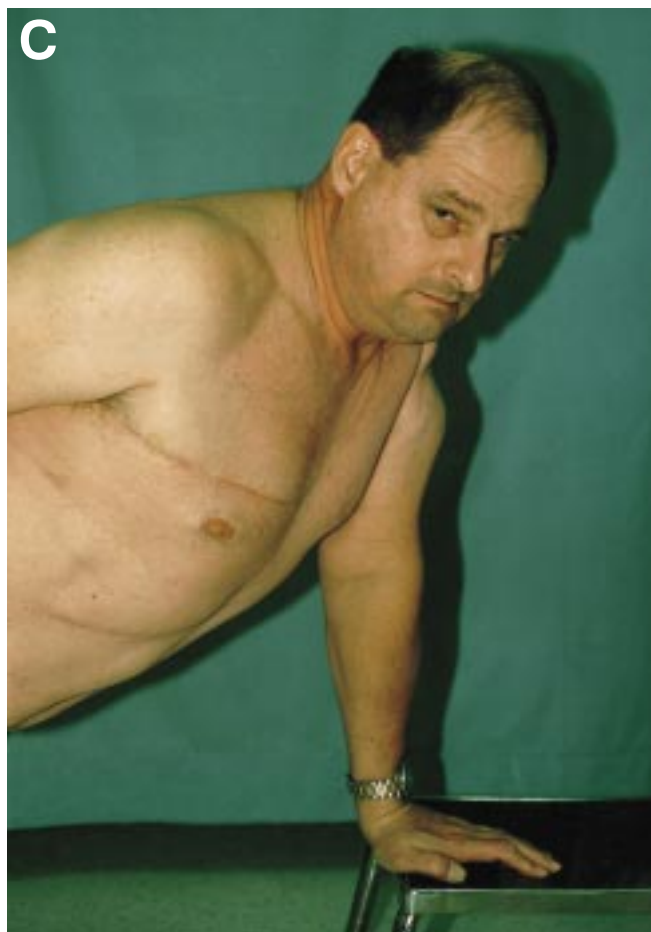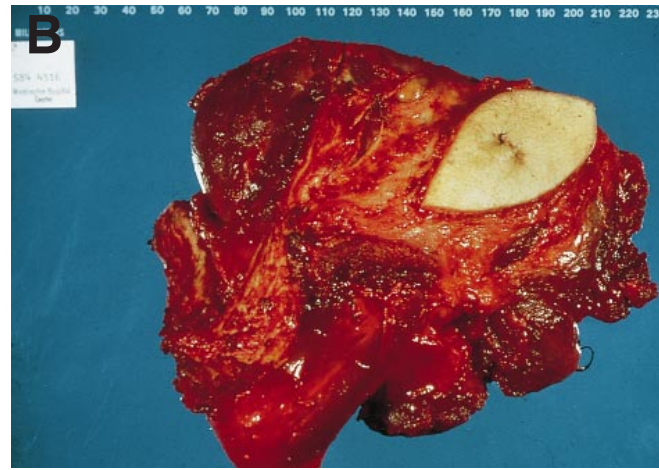
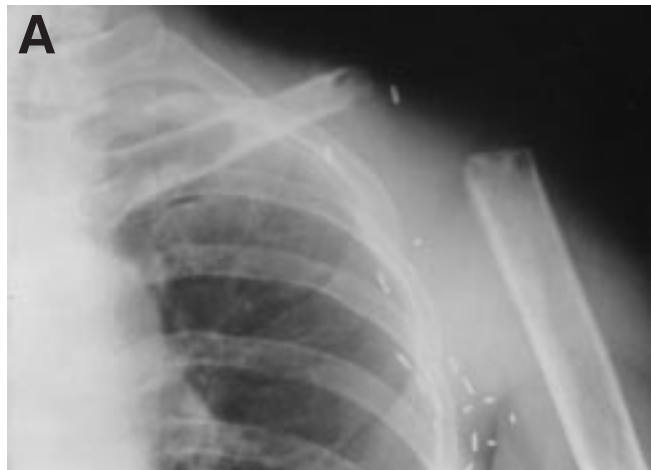The axillary and supraclavicular lymph nodes should be carefully examined preoperatively. Lymph node biopsy may be necessary to determine resectability.

### Suprascapular Tumors

This is a difficult area to evaluate by physical exam and even with modern imaging techniques. Large tumors in this location often extend into the anterior and posterior triangles of the neck, making resection difficult or contraindicated, except for purposes of palliation.

## INDICATIONS

A limb-sparing resection is indicated for most low- and high-grade sarcomas of the scapular and soft-tissue

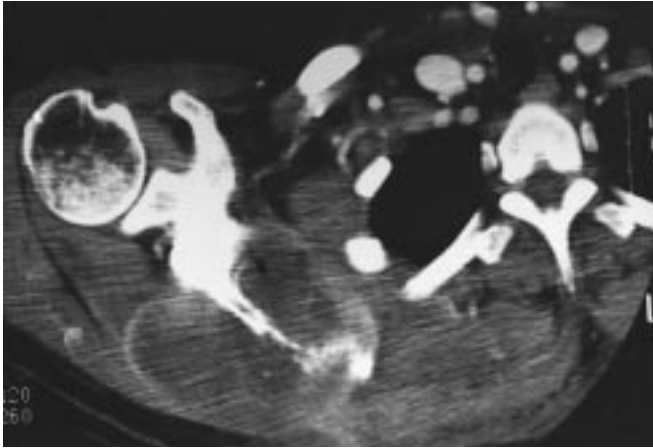


**Figure 34.1** (A) Plain radiograph following a classical Tikhoff–Linberg resection of the scapula and the proximal humerus en-bloc. This is now classified as a Type IV resection. (B) Gross specimen showing the scapula covered by the muscles that attach to the scapula with the biopsy site en-bloc. (C) Clinical photograph 16 years following the photograph shown above, demonstrating a one-handed push-up. This illustrates the excellent shoulder girdle stability following reconstruction without a scapular prosthesis if there are significant muscles available to be transferred to the clavicle and the humerus. (D) The same patient rowing a boat. The clinical appearance of the shoulder is facing the reader.

sarcomas that secondarily invade bone. Contraindications include tumor extension into the axilla with involvement of the neurovascular bundle, and extensive involvement of the adjacent chest wall. Complications from a prior biopsy with extensive contamination of tissues may also make a limb-sparing scapular resection inadvisable.

#### IMAGING STUDIES

Necessary preoperative imaging studies include plain radiographs, computerized tomography (CT) scan, magnetic resonance imaging (MRI), bone scan, arteriography, and occasionally venography. These studies are crucial for evaluation of tumor extension into the chest



**Figure 34.2** CT scan of an extremely large scapular tumor with extension to the chest wall and involvement of all of the adjacent muscles. This patient was not a candidate for a scapular prosthesis. Muscle coverage is required for a prosthesis to be utilized.

wall, axillary vessels, proximal humerus and glenohumeral joint.

CT and MRI are the most valuable means of determining the size and extent of extraosseous disease and its relationship to the axillary vessels, glenohumeral joint and chest wall.

Arteriography can determine vascular involvement as well as vascular anatomy. Displacement of the axillary vessels is indicative of anterior tumor extension into the axilla. This mandates that an anterior approach is necessary to permit safe mobilization of the axillary vessels and the brachial plexus. Axillary venography is performed if there is any clinical suspicion of brachial plexus involvement. Nerve pain and/or distal edema is the hallmark of invasion and not just displacement of the brachial plexus. Occluded axillary veins seen on venography correlate with brachial plexus infiltration and indicate that an amputation may be required. Bone scan may indicate rib involvement and is useful for evaluating proximal humeral extension and metastatic disease.

### BIOPSY

The biopsy site should be carefully selected. It should be located away from the major vessels and nerves and

placed so that it can be widely excised by the definitive resection. Inadvertent contamination of the neurovascular structures or the chest wall must be avoided. Sarcomas of the shoulder girdle rarely require an open biopsy. The majority of sarcomas in this location have an extraosseous (soft-tissue) component; therefore a small-needle or core biopsy should be performed.

Fine-needle or core biopsies should be performed under fluoroscopic or CT guidance unless the mass is easily palpable and located away from the neurovascular bundle. Only one puncture site is required. The needle is then reintroduced through the same puncture site, but the angle is varied so cores can be obtained from several different regions of the tumor. Touch-preps and frozen sections are performed at the time of biopsy to confirm that adequate tissue has been obtained. Cultures are routinely obtained irrespective of the suspected diagnosis because infection may simulate any malignancy.

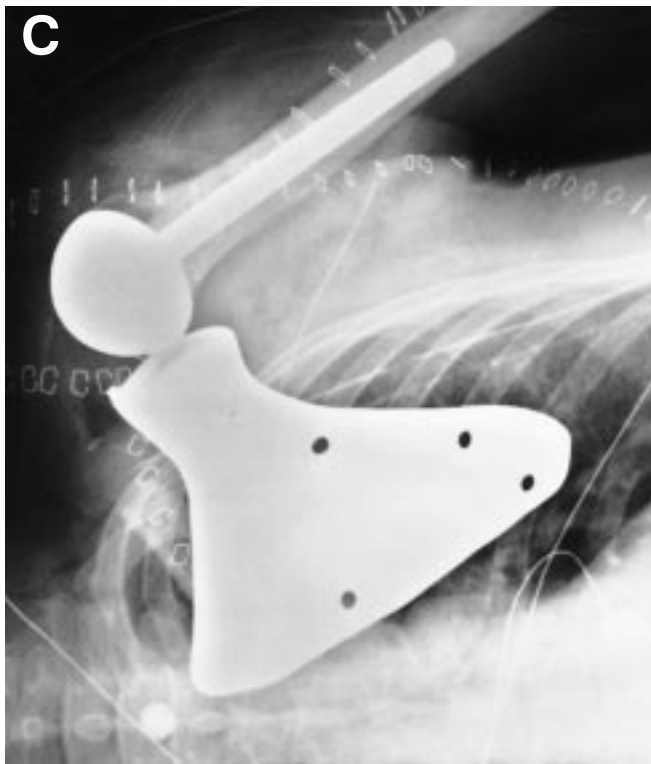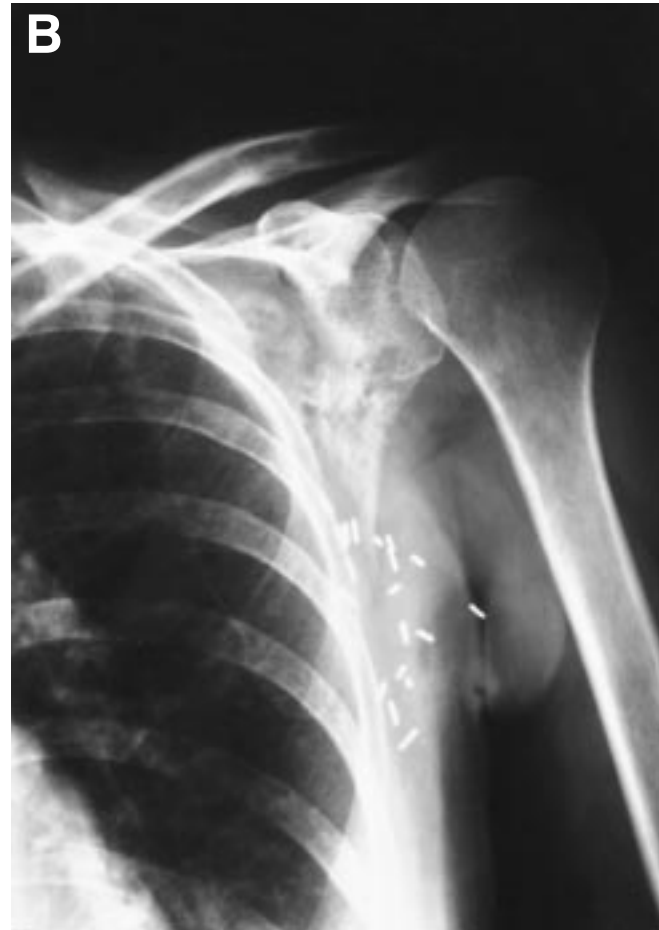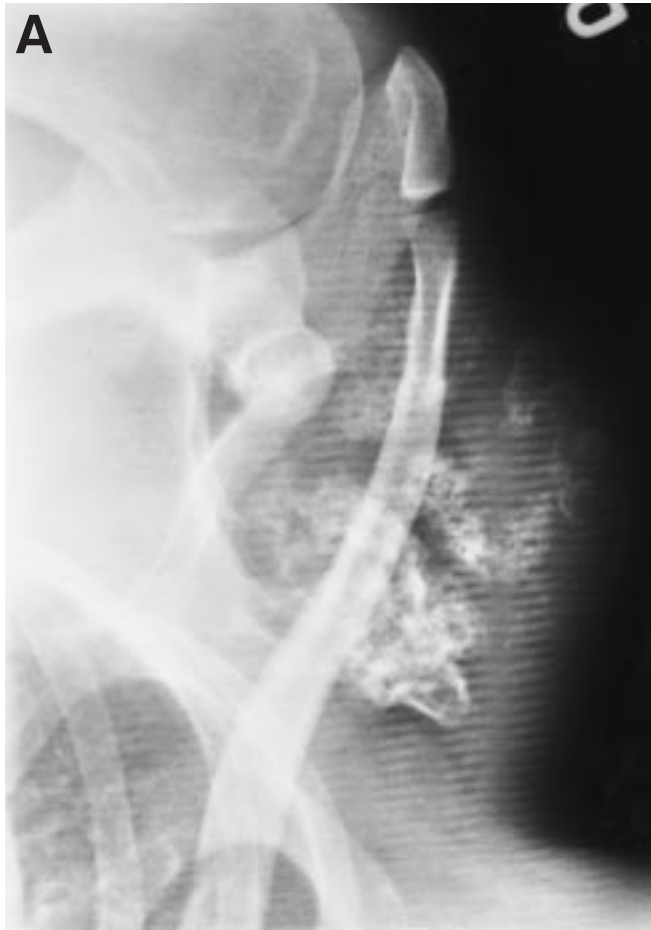### Scapula

Biopsies of the scapular body are more difficult to perform than biopsies in other sites; however they are crucial in determining the final operative procedure. The biopsy site should be along the intended incision site of the resection. A posterior needle biopsy is recommended for tumors arising within the body of the scapula; the anterior approach should be avoided. Biopsies of tumors of the scapula should be performed along the lateral or axillary aspect of the scapula. The biopsy should not be along the vertebral (medial) border or directly posterior through the potential skin flap.

### SURGICAL GUIDELINES

1. A combined anterior and posterior approach is utilized (utilitarian shoulder girdle incision).
2. The axillary vessels and plexus are explored and mobilized anteriorly. This requires the pectoralis major to be detached and reflected for adequate exposure.
3. The posterior incision permits the release of all muscles attaching to the scapula.
4. The glenohumeral joint is removed extra-articularly. The osteotomy is performed below the level of the joint capsule.
5. The remaining humerus is supported from the clavicle with Dacron tape (static suspension) and the conjoin tendon (dynamic suspension).
6. A scapular prosthesis may be utilized if significant musculature remains; specifically the deltoid, trapezius, rhomboids, and latissimus dorsi muscles are required for a prosthetic replacement.
7. Postoperatively, a sling is required for 4–6 weeks.





**Figure 34.3** (A) Typical chondrosarcoma of the scapula with a large extrasosseous component showing soft-tissue calcifications. Chondrosarcoma is the most common primary bone tumor of the scapula. It usually occurs past the third decade of life. (B) Ewing's sarcoma of the scapula. Ewing's sarcoma usually occurs in patients less than 20 years of age. This patient had undergone a partial resection with recurrence that now requires a total scapular resection. (C) Total scapula prosthesis. This is the original design utilized in the late 1980s. Note that there are only a few holes for muscle attachments and the scapula body is solid.

## SURGICAL TECHNIQUE

### Extra-articular Total Scapula and Humeral head Resection (Type IV); The Tikhoff–Linberg Procedure (Figure 34.1)

This procedure is indicated for most high-grade sarcomas of the scapula, especially if tumor extends anteriorly or laterally and involves the rotator cuff, glenoid, or glenohumeral joint. It is also used for some low-grade sarcomas of the scapula and for periscapular soft-tissue sarcomas. In general, a total scapulectomy (Type III) resection is a poor cancer operation.

The resection consists of en-bloc removal of the scapula, distal clavicle, and proximal humerus with preservation of the arm. It includes removal of all the muscles arising from the scapula and inserting on the proximal humerus and an extra-articular resection of the glenohumeral joint. The interval between the tumor and neurovascular bundle must be carefully evaluated; this requires surgical exploration prior to resection. Occasionally, the deltoid muscle and the axillary nerve can be preserved. In this situation a total scapula prosthesis may be used.

#### Reconstruction

Soft-tissue reconstruction is necessary to provide stability and avoid a flail upper extremity. The extent of proximal humeral resection and the muscles remaining available for reconstruction and coverage dictate the type of reconstruction performed. The preferred techniques include a standard dual suspension (i.e. static and dynamic) technique using Dacron tape and the remaining bone and muscle for reconstruction or, if adequate soft tissue is preserved, a total scapula and shoulder joint prosthesis (Figure 34.6).

#### Standard Reconstruction (Dual Suspension)

The dual suspension technique is performed. Dacron tape (3 mm) is used to suspend the remaining humerus from the distal clavicle. The biceps, coracobrachialis and triceps are reattached through drill holes in the distal clavicle. If the deltoid muscle has been preserved, it is tenodesed anteriorly to the pectoralis major and trapezius muscles to further reconstruct the anterior aspect of the shoulder girdle.

## SCAPULAR PROSTHETIC RECONSTRUCTION

Experience with total scapular replacement is limited but increasing (Figure 34.4). We have performed 25 scapular prosthetic replacements. Three issues need to

be addressed for successful prosthetic reconstruction following a Type IV resection:

1. replacing the proximal humerus and humeral joint surface;
2. creating a new glenohumeral joint;
3. providing soft-issue attachments to both the humeral and scapular components to improve stability and function.

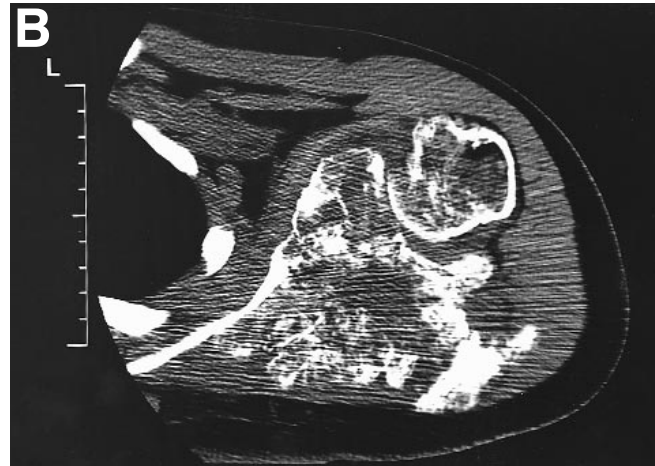
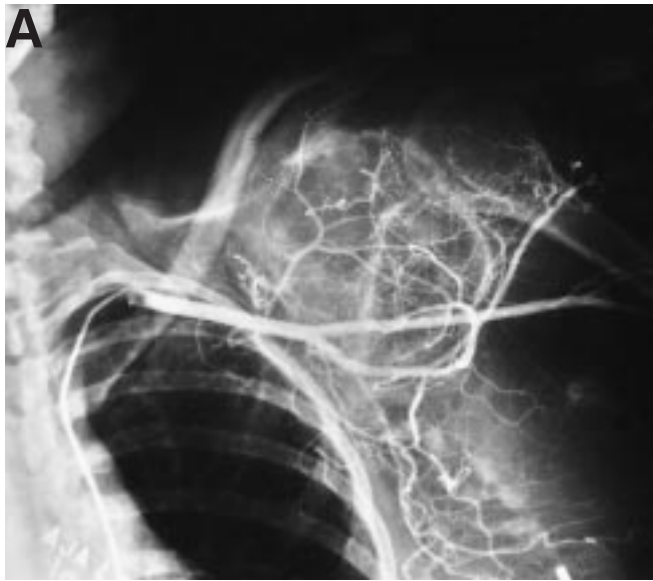
A total scapular and shoulder joint prosthesis is used for reconstruction following a Type IV resection. It is imperative that adequate muscle be preserved for complete coverage of the prosthesis following soft-tissue reconstruction. This requires the deltoid, trapezius, rhomboids, and latissimus dorsi muscles. If limited muscle remains following tumor resection, the standard dual suspension reconstruction should be performed.

Several prosthetic devices are available for reconstruction of the glenohumeral joint. Most are constrained or semiconstrained devices; i.e. they provide shoulder stability. The body of the prosthetic scapular design has large fenestrations that decrease its weight and promote tenodesis of the overlying muscle reconstruction to the underlying serratus muscle and chest wall. Multiple holes along the axillary, glenoid, and vertebral borders of the scapular component, as well as holes or loops along the proximal humeral component, are available for soft-tissue reattachments.

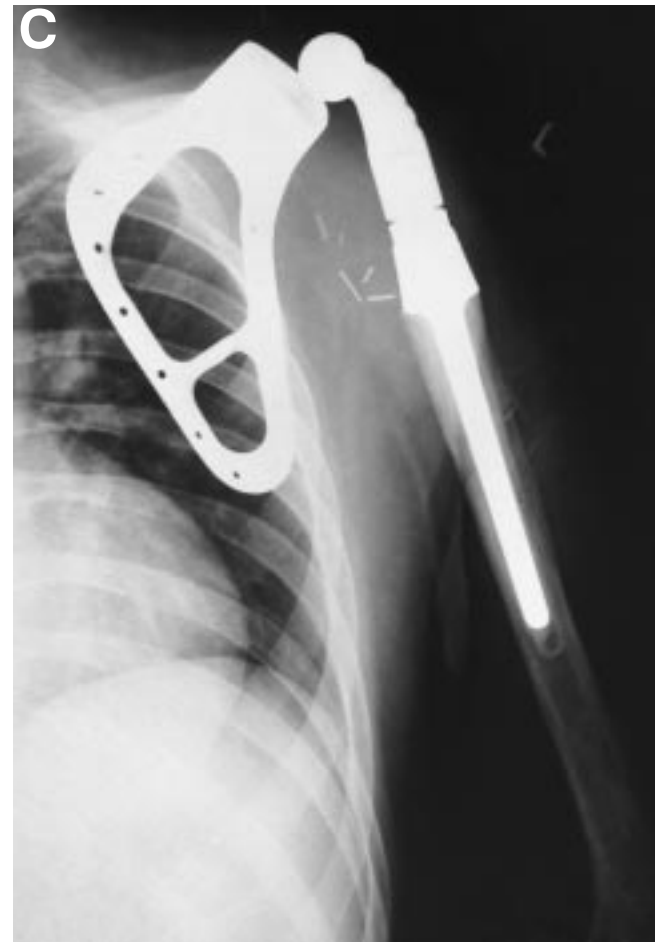The proximal humeral prosthetic component or the humeral resurfacing component (if minimal bone resection is required) is cemented into the remaining humeral diaphysis using the techniques previously described.

### CONSTRAINED TOTAL SCAPULAR PROSTHESIS (Figure 34.4D)

The rotator cuff muscles actively stabilize the glenohumeral joint during active shoulder abduction and forward flexion. Their function is coupled with the deltoid and trapezius muscles to produce 180° of motion. During glenohumeral abduction, deltoid contraction produces an upward force vector on the proximal humerus shaft while the rotator cuff produces an inward and downward force on the humeral head. The rotator cuff prevents upward humeral migration by stabilizing the humeral head in the glenoid fossa, thus creating a fixed fulcrum at the glenohumeral joint. The upward force produced by the deltoid is converted into angular acceleration at the glenohumeral joint, which facilitates shoulder abduction/elevation. Without the rotator cuff the humerus translates superiorly with deltoid contraction. The forces produced by the deltoid are dissipated and fail to result in angular acceleration.



**Figure 34.4** (see also following page) Large osteosarcoma of the scapula with proximal humeral extension. (A) Angiogram showing a large tumor of the scapula displacing axillary vessels. (B) CT scan post-induction chemotherapy with shrinkage of the tumor and reossification of the bone. The tumor still extended around the capsule of the humerus and required an extra-articular resection of the scapula and the proximal humerus. (C) Postoperative radiograph showing a scapula and proximal humeral replacement. (D) Muscle force vectors across the glenohumeral joint: normal anatomy, non-constrained (Gore-Tex aortic graft) total scapular reconstruction and constrained total scapular reconstruction. Under normal conditions the rotator cuff provides a medially and inferiorly directed force vector on the humeral head which stabilizes it against the glenoid. Contraction of the deltoid is efficiently converted into angular acceleration of the glenohumeral joint (large arrow) which results in abduction. When a Gore-Tex aortic graft is used to stabilize separate total scapular and proximal humerus components the inherent elasticity in the Gore-Tex permits upward humeral migration with deltoid contraction. Deltoid contraction is not efficiently converted into angular acceleration of the glenohumeral joint (smaller arrow). The constrained glenoid mechanically ensures stability and theoretically restores rotator cuff function. It stabilizes the humeral head within the glenoid and prevents upward humeral migration. Deltoid contraction can be efficiently converted into angular acceleration (abduction) of the glenohumeral joint. (E) Gore-Tex graft that is utilized for reconstruction at the capsule; a mechanism between the scapula and the proximal humerus.



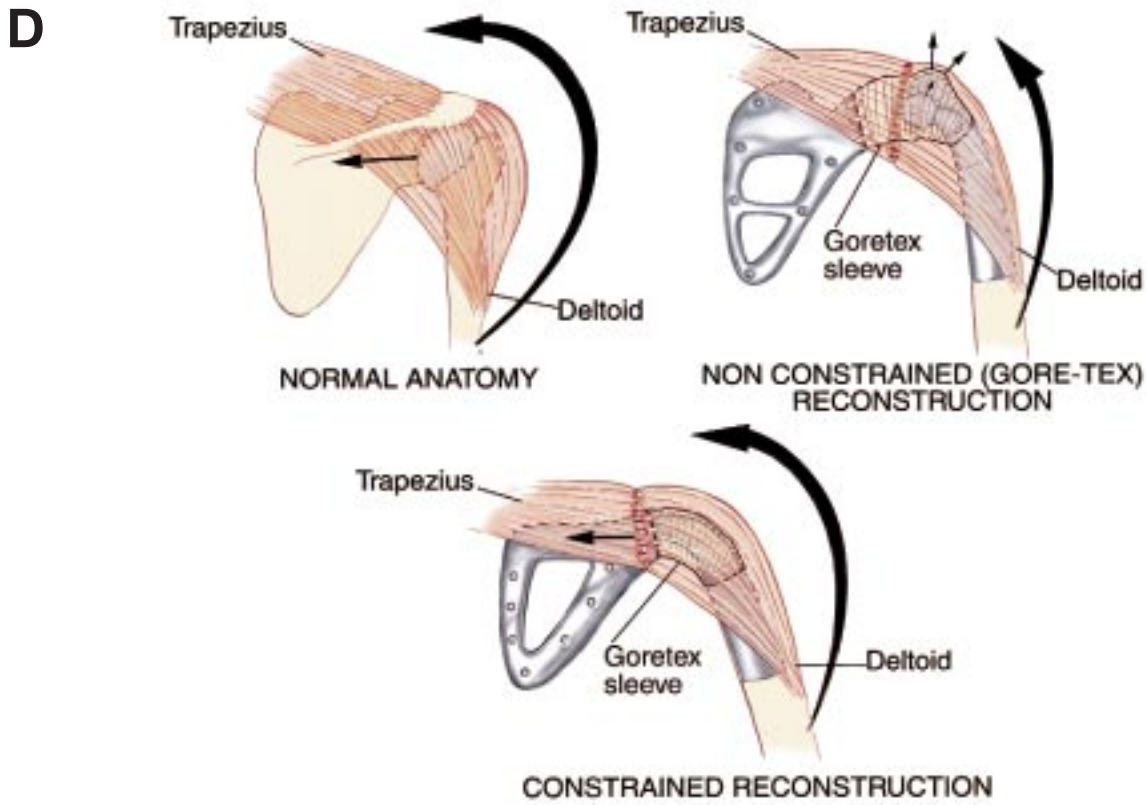


Figure 34.4 D,E




Figure 34.5 (see also following page) (A) Total scapula prosthesis. Note the holes along the vertebral and axillary border as well as the glenoid for reattachments of the adjacent muscles with Dacron tape. The proximal humerus snap fits into the new glenoid. (B,C) Surgical technique of reconstruction of the capsule mechanism of the total scapula and proximal humerus with a Gore-Tex graft. (B) shows the graft sewn in place along the glenoid rim with Dacron tape. (C) The Dacron tape is pulled over the proximal humerus and sutured through the corresponding holes with Dacron tape. This technique re-creates the stability of the glenohumeral joint. (D) Postoperative epineural injection of a brachial plexus catheter utilized for postoperative pain relief. We routinely place catheters in the neural sheath of all patients undergoing resection and amputation about the shoulder girdle prior to closing the wound. This provides excellent pain relief during the perioperative period. Note that the dye (solid arrow) is tracking proximally (curved arrow indicates the epineural catheter in the nerve sheath). This catheter is uneventfully removed on the fourth to fifth postoperative day.



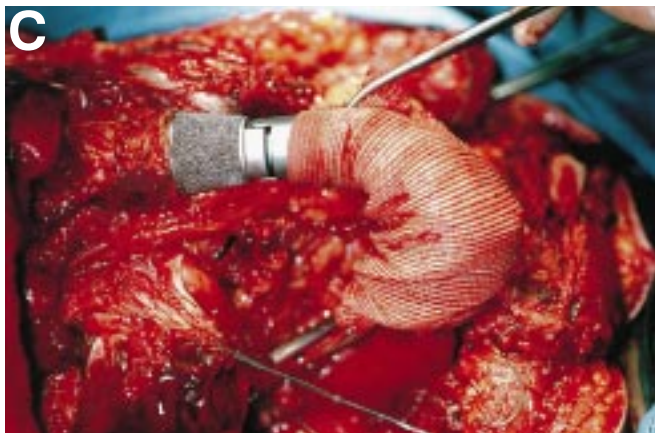
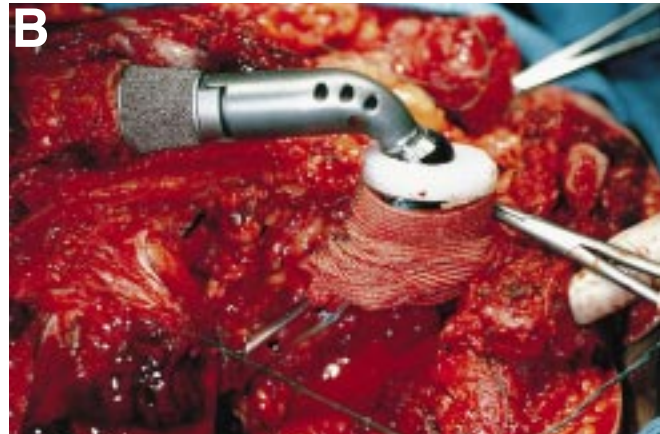
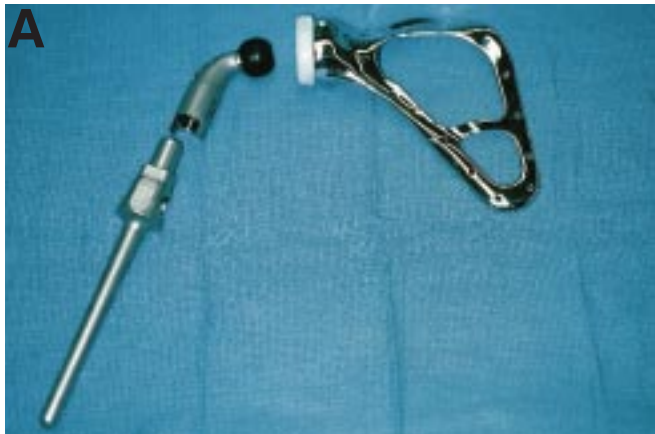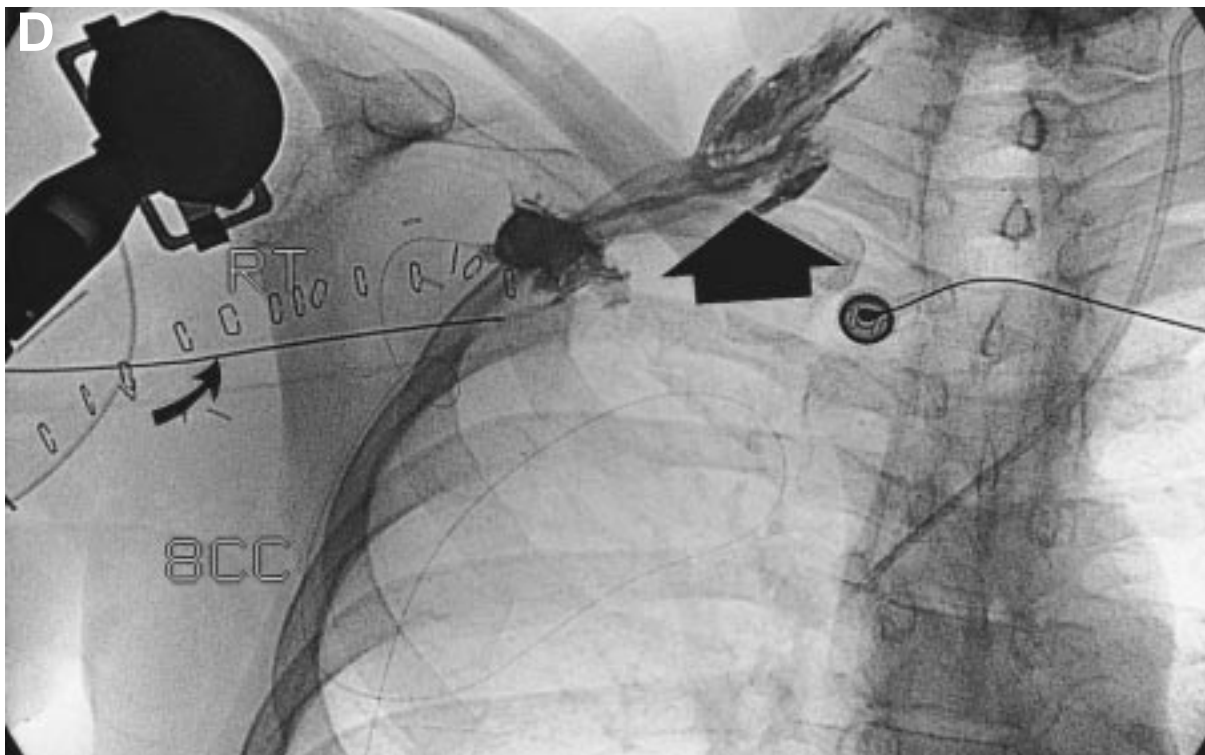
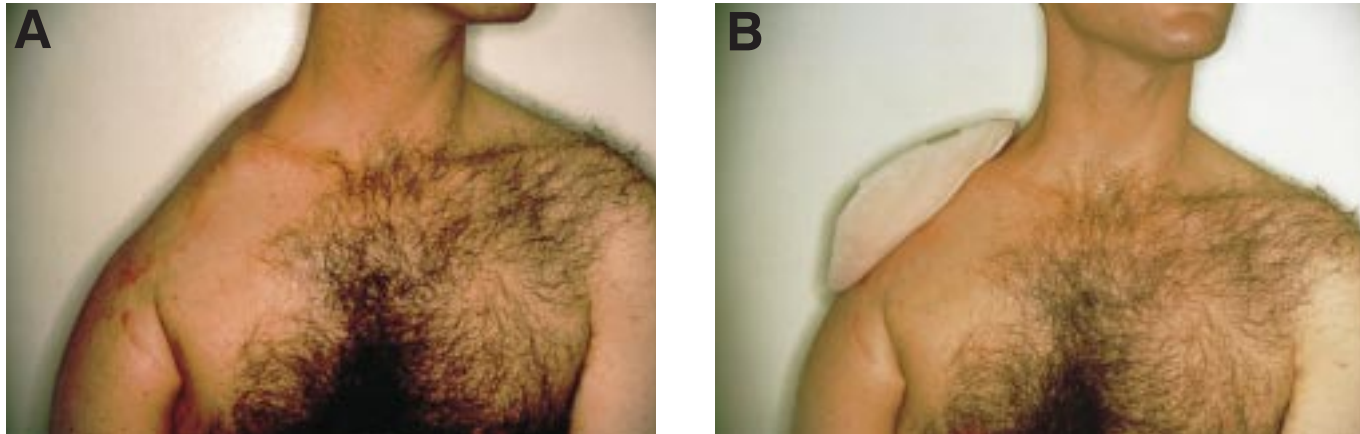


Figure 34.5 A-D





**Figure 34.6** (A) Clinical photograph following a Tikhoff-Linberg (Type IV B) resection without scapular replacement. (B) Cosmesis can be re-established with a simple shoulder pad attached to the patient's shirt.

The major advantage of the constrained (scapula) glenohumeral joint in lieu of a nonconstrained scapula is that it increases shoulder stability but, most importantly, passively substitutes for the function of the absent (resected) rotator cuff by creating a fixed fulcrum at the glenohumeral joint. This permits the deltoid to function more efficiently.

High-grade sarcomas arising from the scapular require en-bloc resection with the rotator cuff. Anatomic reconstruction with a total scapular replacement recreates both glenohumeral and scapulothoracic mechanisms which are necessary for optimal shoulder function. Traditionally, separate scapular and proximal humerus components were utilized and stabilized to each other with a Gore-Tex aortic graft. The inherent elasticity in the aortic graft was not ideal for replacing the function of the rotator cuff and occasionally failed by rupturing. In an effort to improve stability at the glenohumeral joint, and replace the function of the rotator cuff, a constrained total scapular replacement, modeled after a bipolar hip hemiarthroplasty, was designed. The constrained glenoid provides a locking mechanism into which the humeral head is snapped without compromising motion. The locking mechanism passively substitutes for the rotatory cuff by securing the humeral head within the glenoid fossa that creates a fixed fulcrum at the glenohumeral joint. Deltoid contraction can be efficiently translated into angular acceleration at the joint and therefore active glenohumeral abduction and elevation. Clinically, our experience has shown approximately a 45–60° abduction gain with the new constrained total scapula.

#### Glenohumeral Capsule Reconstruction (Figure 34.4E)

The glenohumeral joint and capsule are reconstructed using a 32-mm Gore-Tex aortic graft that is sewn over the prosthetic scapular neck, attached with Dacron tape, and sutured through holes of the proximal humeral component using multiple Dacron tapes. This stabilizes the new glenohumeral joint (Figure 34.5).

#### Muscle Reconstruction

The anterior muscle reconstruction follows the techniques used after Type V resections. The biceps and coracobrachialis are sutured together and reattached to the clavicle. The pectoralis major muscle is closed anteriorly over the new joint. The posterior muscle reattachment and reconstruction over the prosthetic scapula are described below.

#### Posterior Muscle Reconstruction

The levator scapulae is tenodesed to the trapezius muscle and sutured to the posterior deltoid muscle at the level of the previous position of the scapular spine. The rhomboids are sutured to the cut edges of the serratus anterior or teres muscles if adequate length remains; otherwise these muscles are sutured to the chest wall or the superior border of the latissimus dorsi.

If a total scapular prosthesis has been used, reconstruction of the muscles over the entire prosthesis is imperative. The scapular prosthesis is laid on the

chest wall on top of the remaining serratus anterior muscle. The teres major and minor muscles (if present) are then attached to the axillary border of the scapular prosthesis through the fenestrations. Medially, the rhomboids and levator scapulae muscles are reattached. The latissimus dorsi muscle is advanced superiorly to cover the body of the prosthesis. The trapezius and the posterior deltoid muscles are then tenodesed to provide complete coverage of the prosthesis.

### Skin Closure

Large-bore suction catheters or a 28-gauge chest tube are used for drainage. The flaps are closed using nonabsorbable suture, their undersurface is tacked to the underlying muscle to decrease dead space. The skin is closed using staples or suture. Epineural catheters are routinely used with a continuous marcaine (4–8 ml of 0.25% marcaine) infusion for 3–5 days (Figure 34.5D).

## TOTAL SCAPULECTOMY

### Type III (Intra-articular Scapular Resection)

Total scapulectomy is primarily indicated for sarcomas (usually low-grade) of the scapular body (below the scapular spine). Preoperative considerations are similar to those of the Tikhoff–Linberg resection. If tumor extends anteriorly, or laterally to involve the glenoid or rotator cuff, this procedure is not recommended. An extra-articular resection (Type IV) should be performed. In general, total scapulectomy (Type III resection) is a poor operation to perform for most sarcomas.

### Position and Incision

The patient is placed in a semilateral position with the arm prepared and draped free for intraoperative manipulation. A posterior incision is performed and skin flaps are created in a method similar to that used for the Tikhoff–Linberg (Type IV) resections.

### Muscle Release

All muscles are transected away from the bone. This process begins with release of the posterior deltoid from the acromion and scapular spine and continues with release and retraction of the trapezius muscle. The rhomboid muscles are released starting at the inferior angle of the scapula. The tip is then elevated and the scapula is retracted away from the chest wall as muscle release continues medially, laterally, and then superiorly. This permits manual exploration of the chest wall and axilla.

### Axillary Exposure

The inferior tip of the scapula is rotated, and traction is applied with the arm abducted. This permits access to and identification of the axillary contents, which are then bluntly retracted away from the operative field.

### Neurovascular Bundle

The neurovascular structures are approached from the back, unless the tumor has an anterior extraosseous component. They are visualized as the scapula is retracted cephalad and away from the chest wall. Extreme care should be taken to avoid injuring the axillary nerve near the inferior border of the subscapularis muscle and the musculocutaneous nerve as it exits near the coracoid. An anterior incision is recommended if there is any problem in identifying the neurovascular structures.

### Shoulder Joint Inspection and Release

Once the body of the scapula is free, attention is turned to the shoulder joint. The infraspinatus and supraspinatus muscles are transected and the joint is entered. Dissection proceeds only if the joint appears normal and without tumor extension. The anterior capsule and the subscapularis tendon are transected. The long head of the biceps is identified, tagged with suture, and divided.

### Anterior Resection and Release

The acromioclavicular joint is entered and released or the distal portion of the clavicle is resected with the specimen. As the scapula is gently elevated, the short head of the biceps and the coracobrachialis and pectoralis minor muscles are released from the coracoid. The musculocutaneous nerve must be protected as it passes near the coracoid.

### Reconstruction

The dual suspension technique using Dacron tape to suspend the proximal humerus from the clavicle or a total scapular prosthesis can be employed to reconstruct the defect. A scapular prosthesis should be used only if there is significant muscle remaining to cover the prosthesis and provide stability.

## PARTIAL SCAPULECTOMY

### Type II Resection (Inferior Scapular Body Resection)

This procedure is indicated for low-grade sarcomas and benign lesions of the scapular body. The most common and only practical partial scapular resection involves



the portion inferior to the scapular spine. This resection retains sufficient bone and shoulder girdle musculature so that a formal reconstruction is not necessary. The most common indications are large sessile osteochondroma and low-grade chondrosarcoma.

### Posterior Approach and Resection

The incision and approach is identical to that used for Type III resections. After release of the trapezius muscle the resection begins inferiorly with release of the latissimus dorsi from the inferior angle and subsequent elevation of the tip of the scapula. The rhomboid muscles are released medially, and the teres major and minor laterally. If the infraspinatus muscle can be saved, it is elevated from the scapular surface. An osteotome or saw is used to osteotomize the scapula just distal to the scapular spine. This portion of the scapula is elevated and the underlying subscapularis muscle is preserved or is divided and removed with the specimen, depending on the type of tumor.

### Reconstruction

The resected portion of the scapula does not need to be replaced (Figure 34.6). Reconstruction consists of suturing the remaining muscles to the retained portion of the scapula with Dacron tape and tenodesing the rhomboids, latissimus dorsi, and teres muscles together.

### PARTIAL SCAPULECTOMY – GLENOID RESECTION

#### Glenoid Resection

Small tumors involving the glenoid, but not the shoulder joint, are extremely rare. The glenoid may be resected with preservation of the medial scapula. Saving the remaining scapula improves suspension of the upper extremity and offers the possibility of shoulder arthrodesis. This is a rare procedure and is not indicated for bone sarcomas.

#### Incision and Resection

The resection is done through the anterior approach, with the incision extending from the acromioclavicular joint superiorly, and along the deltopectoral groove to the level of the deltoid insertion. The anterior deltoid is released from the clavicle, and the pectoralis major is released from its insertion on the proximal humerus. The neurovascular bundle is identified and protected. If the coracoid is to be resected with the glenoid, the pectoralis minor, coracobrachialis, and short head of the biceps are released. If the coracoid will remain, only the

biceps and coracobrachialis muscles are released. The musculocutaneous and axillary nerves are very close to the area of resection and must be protected. The subscapularis tendon is released and the shoulder joint is opened anteriorly. This is followed by circumferential capsular release. The subscapularis is elevated from the undersurface of the scapula, and the osteotomy is performed. The glenoid is then pulled anteriorly, and the posterior muscles are released.

Alternatively, a second posterior incision is utilized to mobilize the deltoid muscle and to expose the posterior aspect of the joint and the glenoid. This permits an accurate osteotomy of the scapula.

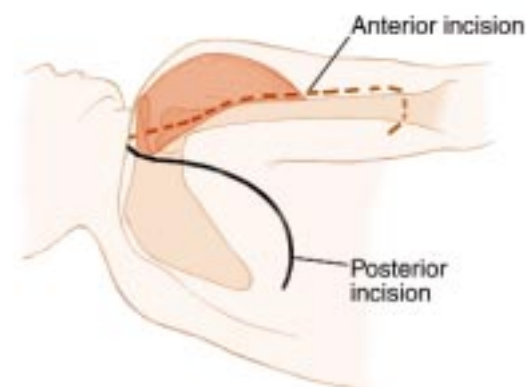
### Reconstruction

The humeral head can be suspended from the remaining scapula and clavicle as previously described for prosthetic reconstruction following Type V resections (see Dual suspension technique). An arthrodesis may be performed.

### THE TIKHOFF–LINBERG RESECTION, PARTIAL AND TOTAL SCAPULECTOMY, AND TOTAL SCAPULAR REPLACEMENT (Figures 34.7–34.13)

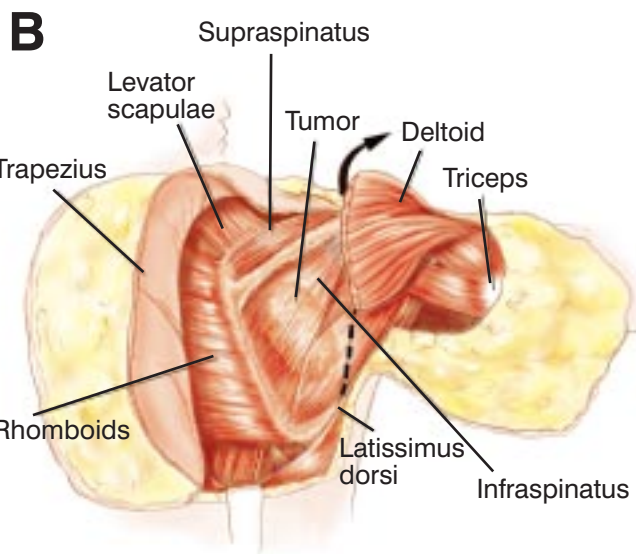
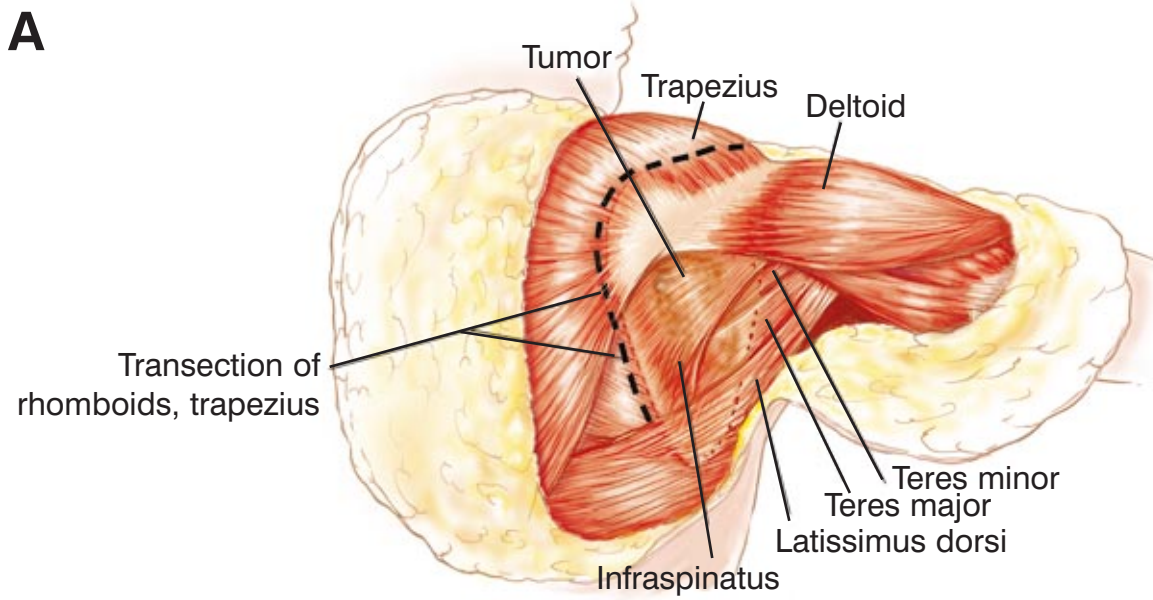
#### DISCUSSION

The Tikhoff–Linberg resection (Type IV) and its variants, total scapulectomy (Type III), and partial



**Figure 34.7** Incision. A utilitarian anterior/posterior approach is utilized. The patient is placed in a lateral position with the affected extremity prepped and draped free. The operative procedure begins with the posterior approach to mobilize the scapula and to explore the retroscapular area to determine if there is any underlying involvement of the chest wall. The anterior approach is utilized following the posterior incision to mobilize the axillary vessels and nerves from any extraosseous component of the tumor. It is unusual to perform a Type III or Type IV scapular resection from the posterior approach alone unless there is minimal soft-tissue extension.

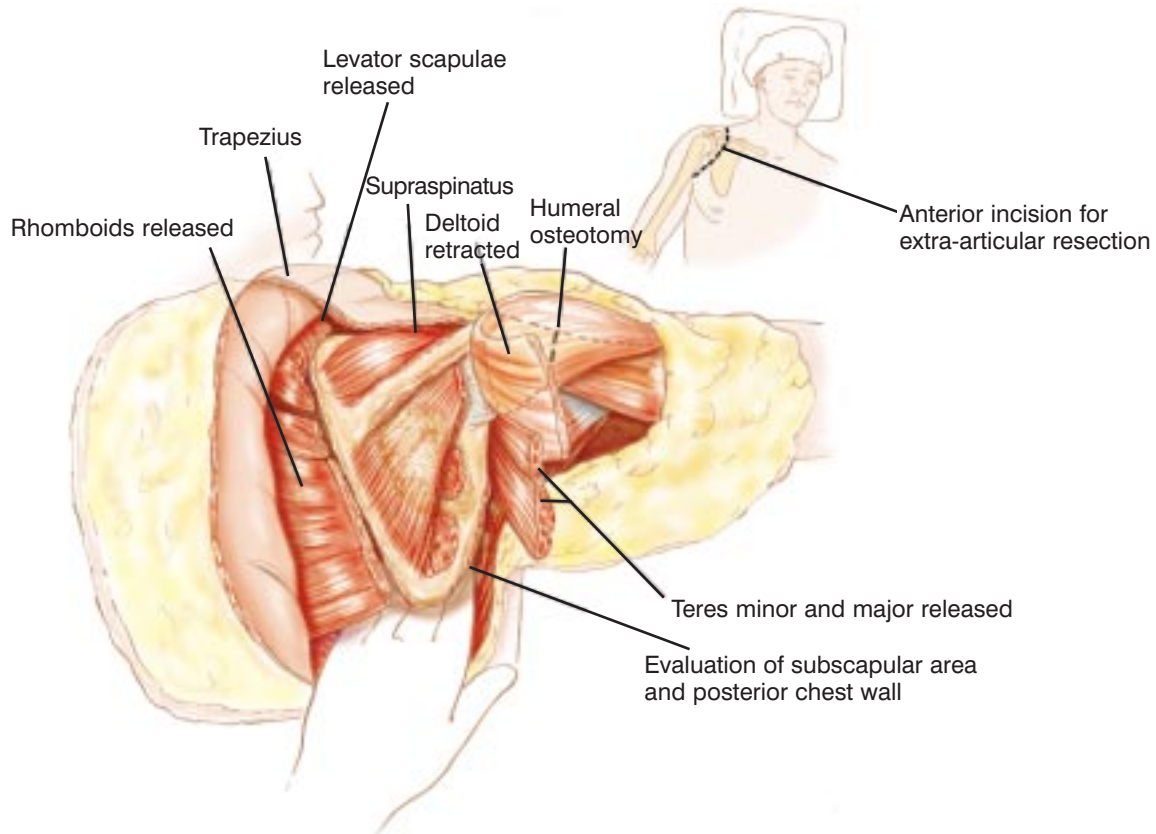




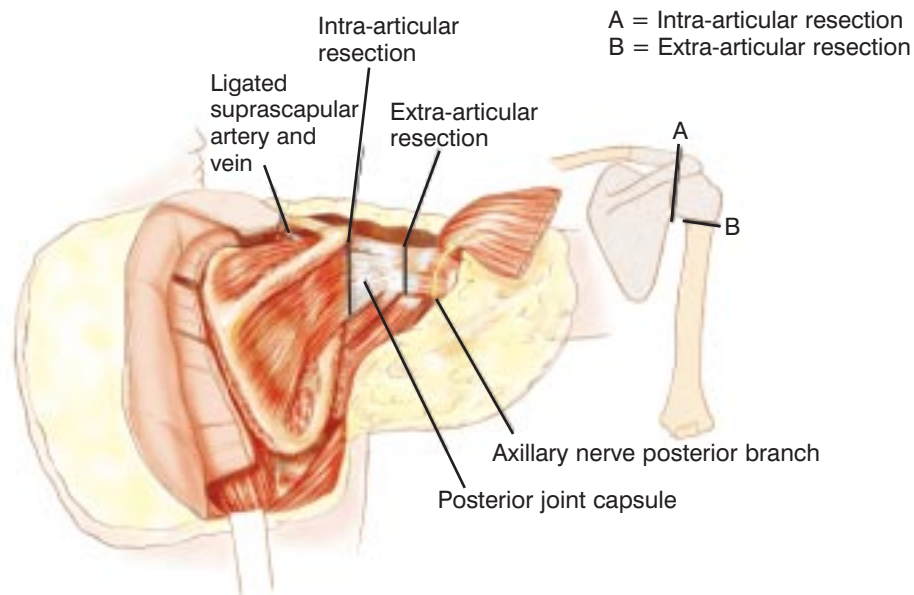
**Figure 34.8** (A) A large posterior fasciocutaneous flap is developed. The rhomboids and trapezius muscles are released from the vertebral border of the scapula and the latissimus dorsi muscle is mobilized but not transected. (B) If the tumor does not involve the deltoid or the trapezius, these muscles are preserved and are reflected off of the scapular spine and acromion.

scapulectomy (Type II) are illustrated. All of these procedures are performed through a combination of an anterior and a posterior approach. The major differences are the status of the glenohumeral joint and the

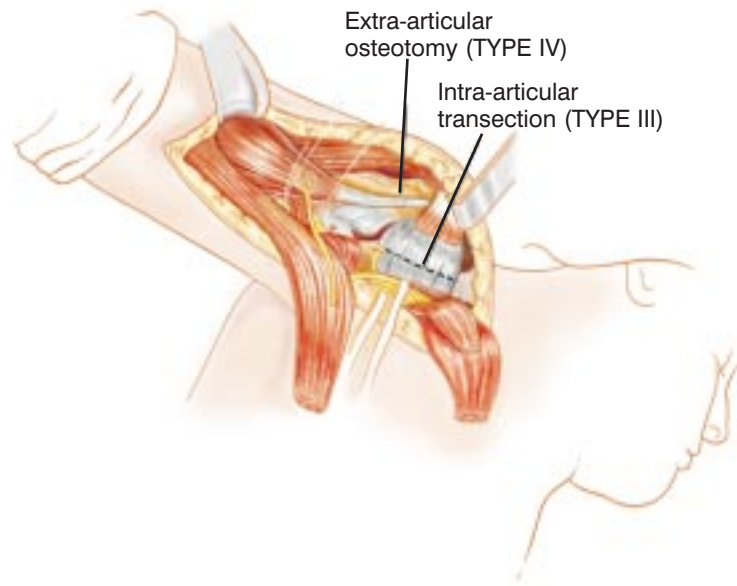
amount of muscle and bone resected. A total scapula replacement can only be performed under strict criteria when there are significant remaining muscles (see above).



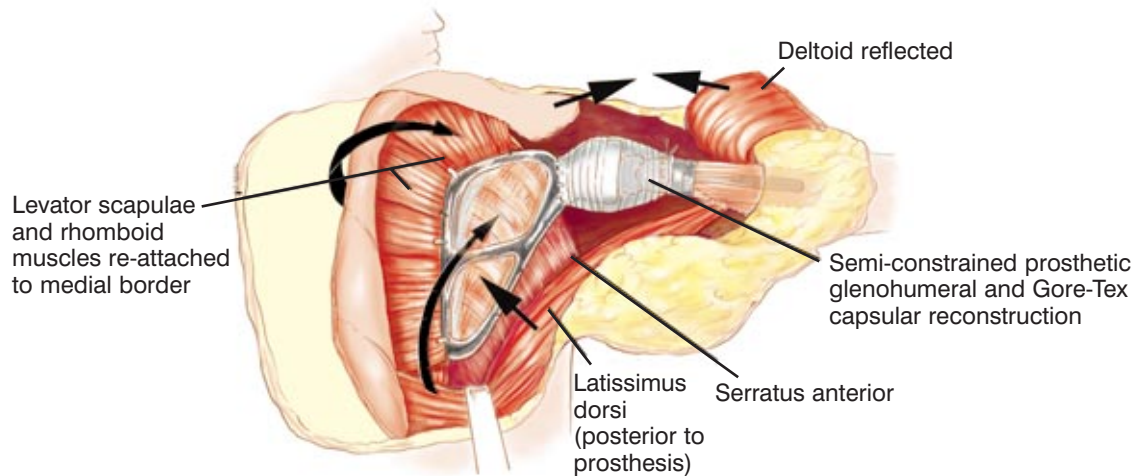
**Figure 34.9** Release of periscapular muscles. The rhomboids, infraspinatus, scapulae, teres major, and teres minor muscles are released from the scapula. The margin of muscle that must remain on the scapula depends on the extent of the tumor. A 1–2 cm cuff of muscle is required for most tumors. The deltoid and the trapezius muscles are reflected. If there is no tumor involvement, then they are preserved. Insert shows the anterior incision for mobilization of the axillary vessels and brachial plexus when there is a large soft-tissue component. This incision is routinely used if an extra-articular incision is to be performed; that is, a true Tikhoff–Linberg resection (Type IV). The classical Tikhoff–Linberg resection does not preserve the deltoid or trapezius muscles; however, in order to provide adequate soft-tissue coverage for the scapular prosthesis, these muscles must be retained. Therefore, a modified Type IV resection is performed.



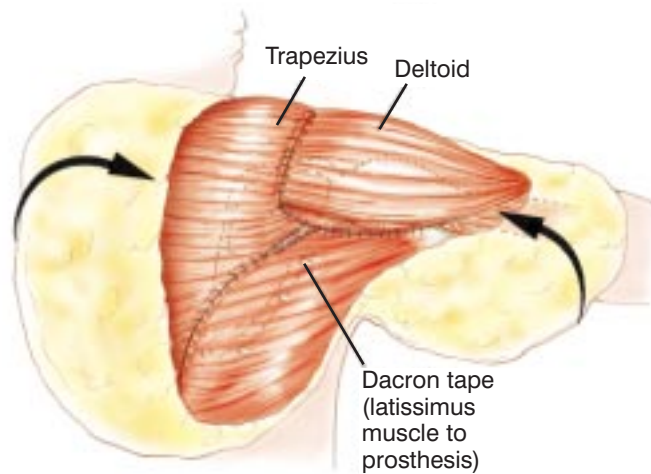
**Figure 34.10** Complete release of the scapula following an intra- or extra-articular resection. The insert shows an intra-articular resection (A) that indicates a total scapulectomy (Type III resection). An osteotomy below the humeral head, i.e. a scapulectomy and extra-articular resection of the glenohumeral joint in conjunction with the scapula, is a classical Tikhoff–Linberg resection. The determination of either a scapulectomy or a Type IV resection is made preoperatively.



**Figure 34.11** Anterior approach and vascular visualization. Most high-grade tumors of the scapula with an extrasosseous component require mobilization of the axillary vessels and the adjacent brachial plexus anteriorly in order to permit a safe resection. This incision is the anterior component of the utilitarian shoulder resection incision as described in Chapter 9. The pectoralis major is released from the humerus to expose the neurovascular structures. An extra-articular resection is performed by an osteotomy inferior to the glenohumeral capsule. An intra-articular resection (Type III resection) is performed by an intra-articular incision.



**Figure 34.12** Prosthetic reconstruction. If there are significant remaining muscles following a Type III or IV shoulder girdle resection, then a scapula prosthesis is utilized. The scapula prosthesis is fenestrated to permit the muscles to tenodesis to themselves, and has holes drilled along the axillary and vertebral borders for fixation with Dacron tapes. The deltoid and trapezius muscles must have been preserved as well as the latissimus dorsi in order to perform a scapula prosthetic replacement. The scapula prosthesis is sutured first to the rhomboid muscles with Dacron tape, and then the latissimus dorsi is rotated over the body of the scapula prosthesis and sutured along the vertebral border. The humeral component is then inserted into the osteotomized proximal humerus. A Gore-Tex graft is utilized to reconstruct the capsular mechanism (Figure 34.5A). The Gore-Tex is sutured to the proximal humerus prosthesis and the glenoid neck on the scapula prosthesis with 3-mm Dacron tape. The muscle closure consists of tenodesis of the deltoid to the trapezius and the latissimus over the rhomboids and to the serratus anterior muscles. The scapula prosthesis fits between the serratus anterior and the latissimus dorsi and rhomboid muscles "as if in a sandwich".



**Figure 34.13** Final muscle closure. The deltoid and trapezius muscles have been preserved and are tenodesed together. The latissimus dorsi is rotated up to the lower border of the deltoid and to the rhomboid muscles. The latissimus is sutured to the holes in the axillary border of the scapula prosthesis and the adjacent musculature using Dacron tape and ethibond sutures, respectively. Postoperatively, a 28-gauge chest tube is used for drainage. The arm is held in a sling for approximately 2 weeks. Epineural catheters for postoperative marcadine infusion are routinely utilized (see Figure 34.5).

## References

1. Liston R. Ossified aneurysmal tumor of the subscapular artery. *Edinb Med J.* 1820;16:66–70.
2. Syme J. *Excision of the Scapula.* Edinburgh: Edmonston & Douglas; 1864.
3. De Nancrede CBG. The end results after total excision of the scapula for sarcoma. *Ann Surg.* 1909;50:1.