33

Proximal Humerus Resection. The Tikhoff–Linberg Procedure and its Modifications

Martin Malawer and James Wittig

OVERVIEW

The proximal humerus is a common site for primary osteosarcomas as well as chondrosarcomas. Metastatic tumors occasionally involve the shoulder girdle and are often treated using the same resection and reconstruction techniques. Limb-sparing resection of the proximal humerus is challenging. Despite their complexity, these resections can be performed in approximately 95% of patients with high- or low-grade sarcomas. Amputations are rarely required.

Endoprosthetic reconstruction is the most common technique for reconstructing large proximal humeral defects. It is used following both intra-articular (Type I) and extra-articular (Type V) resections (see Chapter 9). This is combined with local muscle transfers to create shoulder stability, cover the prosthesis, and provide a functional elbow, wrist, and hand.

The surgical and anatomic considerations of limb-sparing procedures of the proximal humerus and the specific surgical techniques of intra- (Type I) and extra-articular (Type V) resection and reconstruction are described in this chapter. Total humeral replacement is briefly described.

INTRODUCTION

The proximal humerus is one of the most common sites for high-grade malignant bone tumors in the adult. It is the third most common site for osteosarcoma.[1] Tumors in this location tend to have a significant extraosseous component. The proximal humerus may also be involved by metastatic cancer (especially renal-cell carcinoma) and secondarily by soft-tissue sarcomas that require a resection similar to that used for primary bone sarcomas with extraosseous extension.

Approximately 95% of patients with tumors of the shoulder girdle can be treated with limb-sparing resections (Figure 33.1). The Tikhoff–Linberg resection and its modifications are limb-sparing surgical options for bone and soft-tissue tumors in and around the proximal humerus and shoulder girdle. Portions of the scapula, clavicle, and proximal humerus are resected in conjunction with all muscles inserting onto and originating from the involved bones. Careful pre-operative staging and selection of patients whose tumor does not encase the neurovascular bundle, or invade the chest wall, are required. A classification system for resection of tumors in this location is described in Chapter 9. The most common procedure for high-grade sarcomas of the proximal humerus, Type VB, is described (Figure 33.2). The authors do not recommend intra-articular resection (Type I) for high-grade tumors, due to the increased risk of local recurrence.

Optimal function is achieved with muscle transfers and skeletal reconstruction. A prosthesis is used to maintain length and stabilize the shoulder and distal humerus following resection. A stable shoulder with normal function of the elbow, wrist, and hand should be achieved following most shoulder girdle resections and reconstructions performed using the techniques described here.

INDICATIONS

Indications for limb-sparing procedures of the proximal humerus and shoulder girdle include high-grade and some low-grade bone sarcomas, as well as some soft-tissue sarcomas that secondarily invade bone. Occasionally, solitary metastatic carcinomas to the proximal humerus are best treated by a wide excision (Type I resection). The decision to proceed with limb-sparing surgery is based on the location of the tumor and a thorough understanding of its natural history. Absolute contraindications include tumor involvement of the neurovascular bundle or extensive invasion of the adjacent chest wall. Relative contraindications include chest wall extension, tumor contamination of the operative site from hematoma following a poorly performed biopsy or pathologic fracture, a previous infection, or lymph node involvement. Recently, we have treated patients with pathologic fractures with induction chemotherapy, immobilization, and limb-sparing surgery if there is a good clinical response and fracture healing (Figure 33.3).

Figure 33.1 *(see also following page)* Proximal humeral prostheses that have been utilized within the past two decades. (**A**) Initial prosthesis produced by Howmedica with external phalanges. This was a type of prosthesis that was utilized in the 1970s. (**B**) Custom prosthesis with porous coating along the body. This design was utilized during the mid-1980s. (**C**) Modular Replacement System. This prosthesis was designed in 1988 and is currently still utilized.

Malawer Chapter 33 22/02/2001 09:15 Page 519

Figure 33.1 B,C

UNIQUE ANATOMIC CONSIDERATIONS

Resection and reconstruction of the proximal humerus and shoulder girdle is a technically demanding procedure. The local anatomy of the tumor often determines the extent of the operation required. One should be experienced with all aspects of shoulder girdle anatomy and the unique considerations presented: these may be summarized as follows:

Proximal Humerus

Malignant tumors often present with large soft-tissue components (Stage IIB) underneath the deltoid that extend medially and displace the subscapularis and coracobrachialis muscles.[2] Pericapsular and rotator cuff involvement occur early and must be evaluated (Figure 33.4).

Glenohumeral Joint

The shoulder joint appears to be more prone to intra-articular or pericapsular involvement by high-grade bone sarcomas than are other joints. There are four basic mechanisms for tumor spread: direct capsular extension, tumor extension along the long head of the biceps tendon, fracture hematoma from a pathologic fracture, and poorly planned biopsy (Figure 33.4A).

These mechanisms make patients undergoing intra-articular resections for high-grade sarcomas at greater

Malawer Chapter 33 22/02/2001 09:15 Page 520

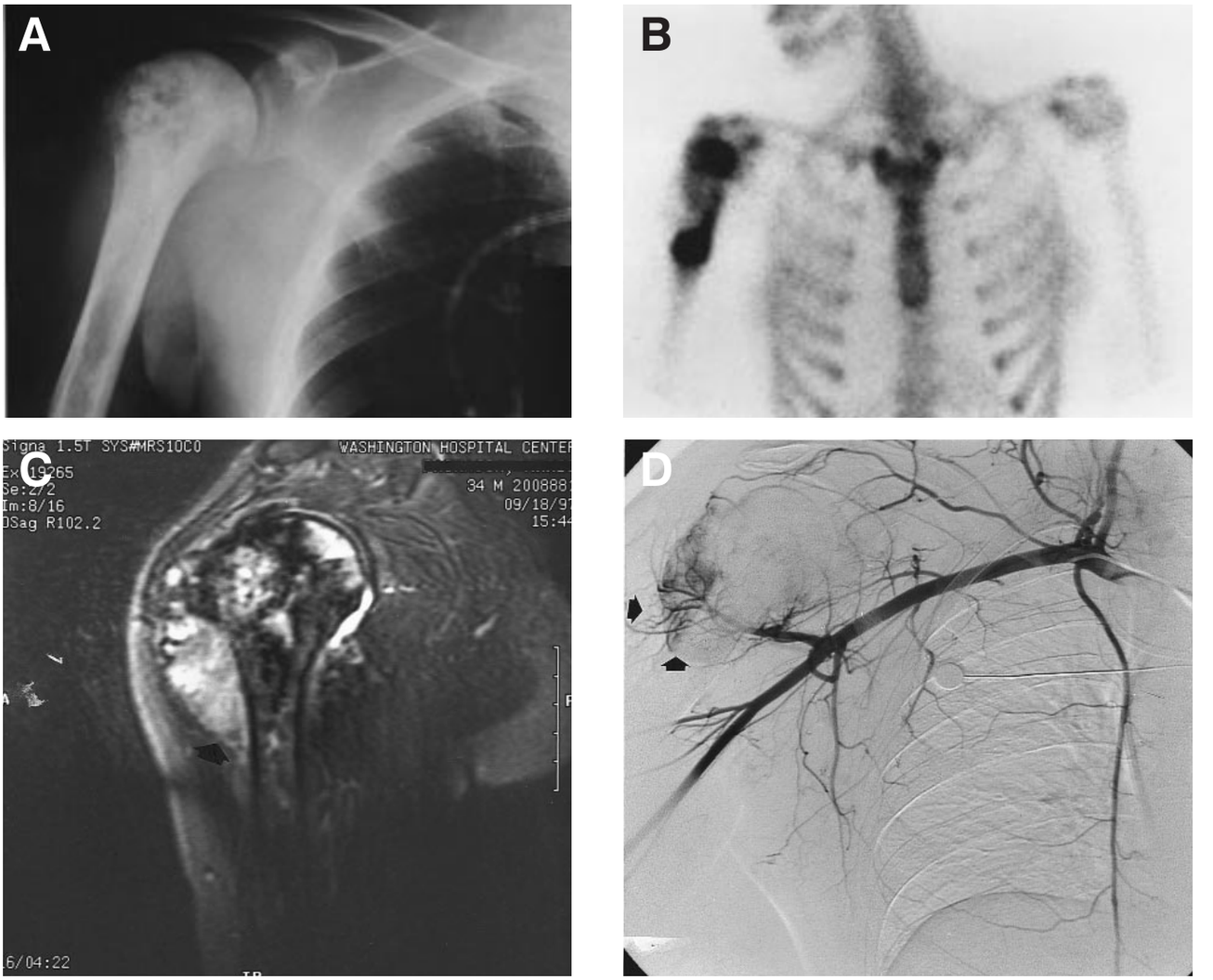

Figure 33.2 *(see also following page)* Typical case of osteosarcoma of the proximal humerus. (**A**) Plain radiograph showing a small sclerosing lesion of the proximal one-quarter of the humerus. This is typical of sclerosing osteosarcoma. (**B**) Bone scan corresponding with (**A**). (**C**) MRI of the same patient shows a large extraosseous component extending below the deltoid muscle (arrow). (**D**) Angiogram following induction chemotherapy showing minimal remaining tumor vascularity. Note that there is some tumor vascularity in the extraosseous component below the deltoid (arrows). There is no tumor vascularity of the main tumor intraosseously. (**E**) Postoperative radiograph showing the Modular Replacement System.

risk for local recurrence than those undergoing extra-articular resections. Therefore, it is often necessary to perform an extra-articular resection for high-grade bone sarcomas of the proximal humerus or scapula.

Neurovascular Bundle

The subclavian artery and vein join the cords of the brachial plexus as they pass underneath the clavicle. Beyond this point the nerves and vessels can be considered as one structure (i.e. the neurovascular bundle). Large tumors involving the upper scapula, clavicle, and proximal humerus may displace the infraclavicular components of the plexus and axillary vessels.

Musculocutaneous and Axillary Nerves

These two nerves are often in close proximity or contact with tumors around the proximal humerus. The musculocutaneous nerve is the first nerve to leave the

Malawer Chapter 33 22/02/2001 09:15 Page 521

E

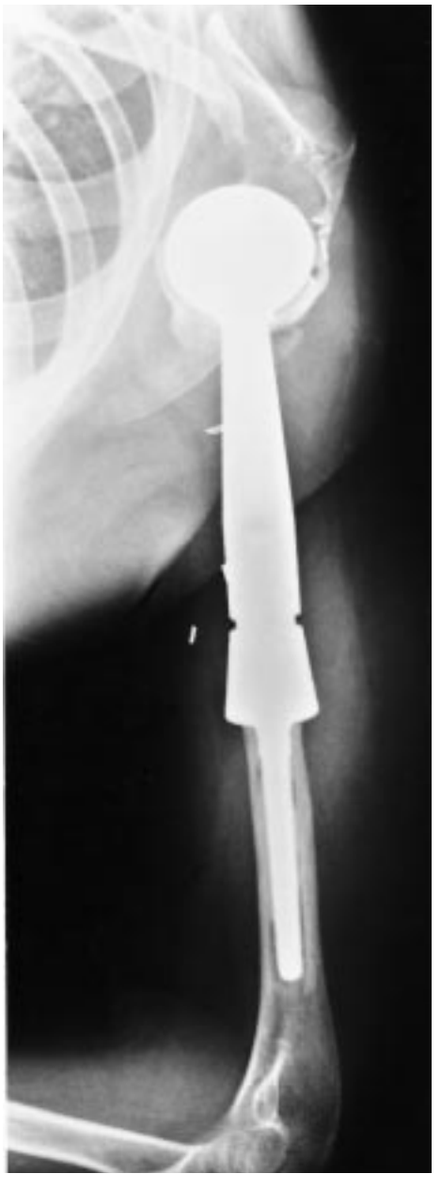

Figure 33.12 E

brachial plexus. It typically leaves the lateral cord just distal to the coracoid process, passes through the coracobrachialis, and runs between the brachialis and biceps. Preservation of the musculocutaneous nerve and short head of the biceps muscle is important to ensure normal elbow function. The path of this nerve may vary extensively (within 6–8 cm of the coracoid) and should be identified prior to any resections because it can be easily injured.

The axillary nerve arises from the posterior cord and courses, along with the circumflex vessels, inferior to the distal border of the subscapularis. It then passes between the teres major and minor to innervate the deltoid muscle posteriorly. Tumors of the proximal humerus are likely to involve the axillary nerve as it passes adjacent to the inferior aspect of the humeral neck, just distal to the joint. Therefore, the axillary nerve and deltoid are almost always sacrificed during proximal humerus resections.

Radial Nerve

The radial nerve comes off the posterior cord of the plexus and continues anterior to the latissimus dorsi and teres major. Just distal to the teres major, the nerve courses into the posterior aspect of the arm to run between the medial and long head of the triceps. Although most sarcomas of the proximal humerus do not involve this nerve, it must be isolated and protected prior to resection.

Axillary and Brachial Arteries

The axillary artery is a continuation of the subclavian artery, and is called the brachial artery after it passes the inferior border of the axilla. The axillary vessels are surrounded by the three cords of the brachial plexus and are tethered to the proximal humerus by the anterior and posterior circumflex vessels. Early ligation of the circumflex vessels is a key maneuver in resection of proximal humeral sarcomas because it allows the entire axillary artery and vein to fall away from the tumor mass. Occasionally, there is anatomic variability in the location of its branches that could lead to difficulty in identification and exploration if not previously recognized. A preoperative angiogram is helpful in determining vascular displacement and anatomic variability.

Final determination of tumor resectability is made at surgery. Early exploration of the neurovascular structures is performed following division of the pectoralis major muscle. This approach does not jeopardize subsequent formation of an anterior flap in patients who require forequarter amputation.

STAGING STUDIES

Appropriate imaging studies are key to successful resections of tumors of the proximal humerus and shoulder girdle. The most useful imaging studies are plain radiography, computerized tomography scans (CT), magnetic resonance imaging (MRI), arteriography, and bone scan. Venography is occasionally required.

1. *Computed tomography*. CT is most useful for evaluating cortical bone changes and is considered complementary to MRI in evaluating the chest wall, clavicle, and axilla for tumor extension.

Malawer Chapter 33 22/02/2001 09:15 Page 522

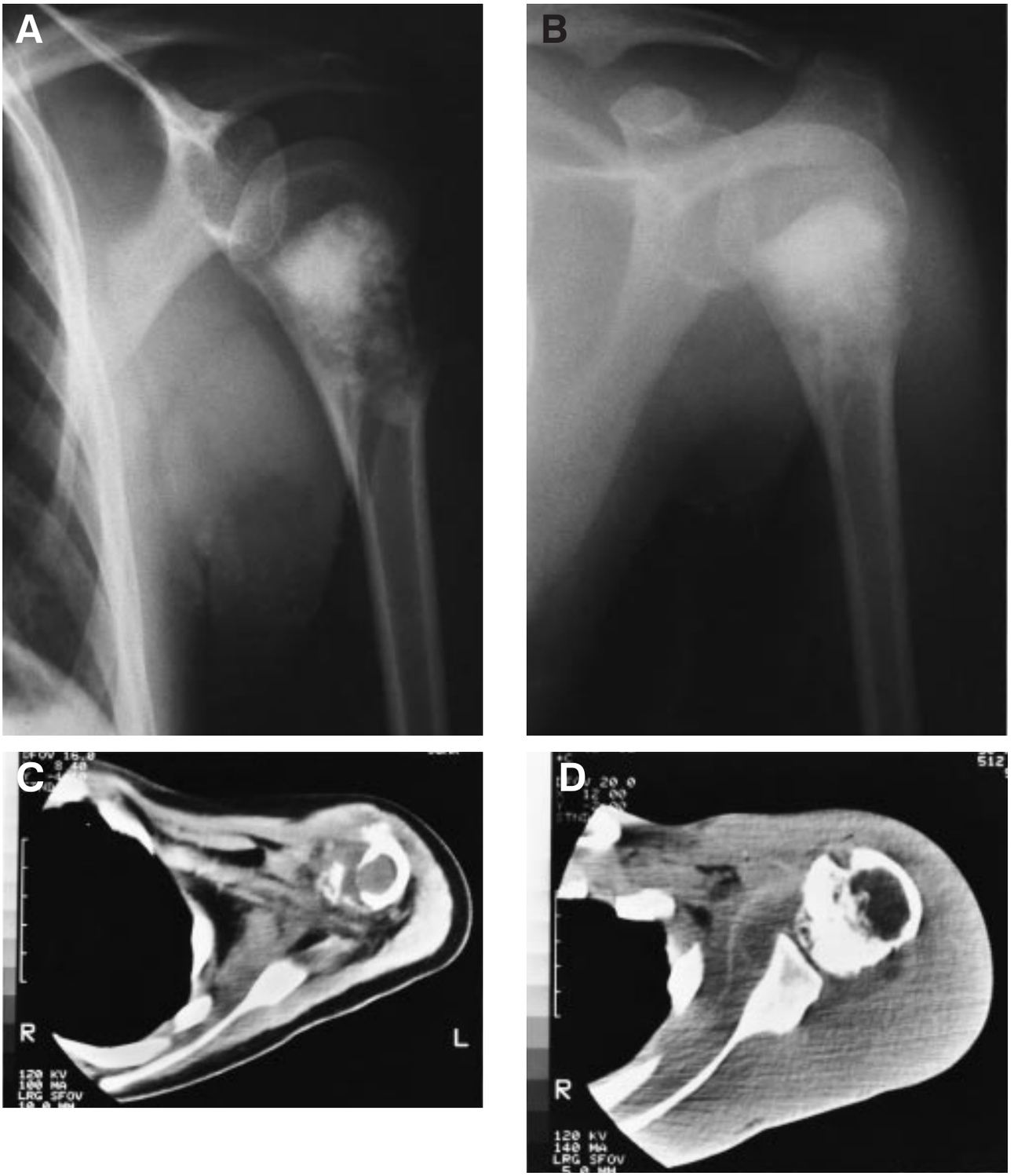

Figure 33.3 Pathologic fracture of a small osteosarcoma of the proximal humerus with minimal displacement. (**A**) Initial photograph showing minimal displacement of the sarcoma. (**B**) Three months following induction chemotherapy with Adriamycin, cisplatinum, and ifosfamide. (**C**) Initial CT scan prior to chemotherapy. (**D**) Postchemotherapy CT scan corresponding to (**B**); showing complete fracture healing. Limb-sparing surgery can be performed following a pathologic fracture if there is a good response to induction chemotherapy with fracture healing.

Malawer Chapter 33 22/02/2001 09:15 Page 523

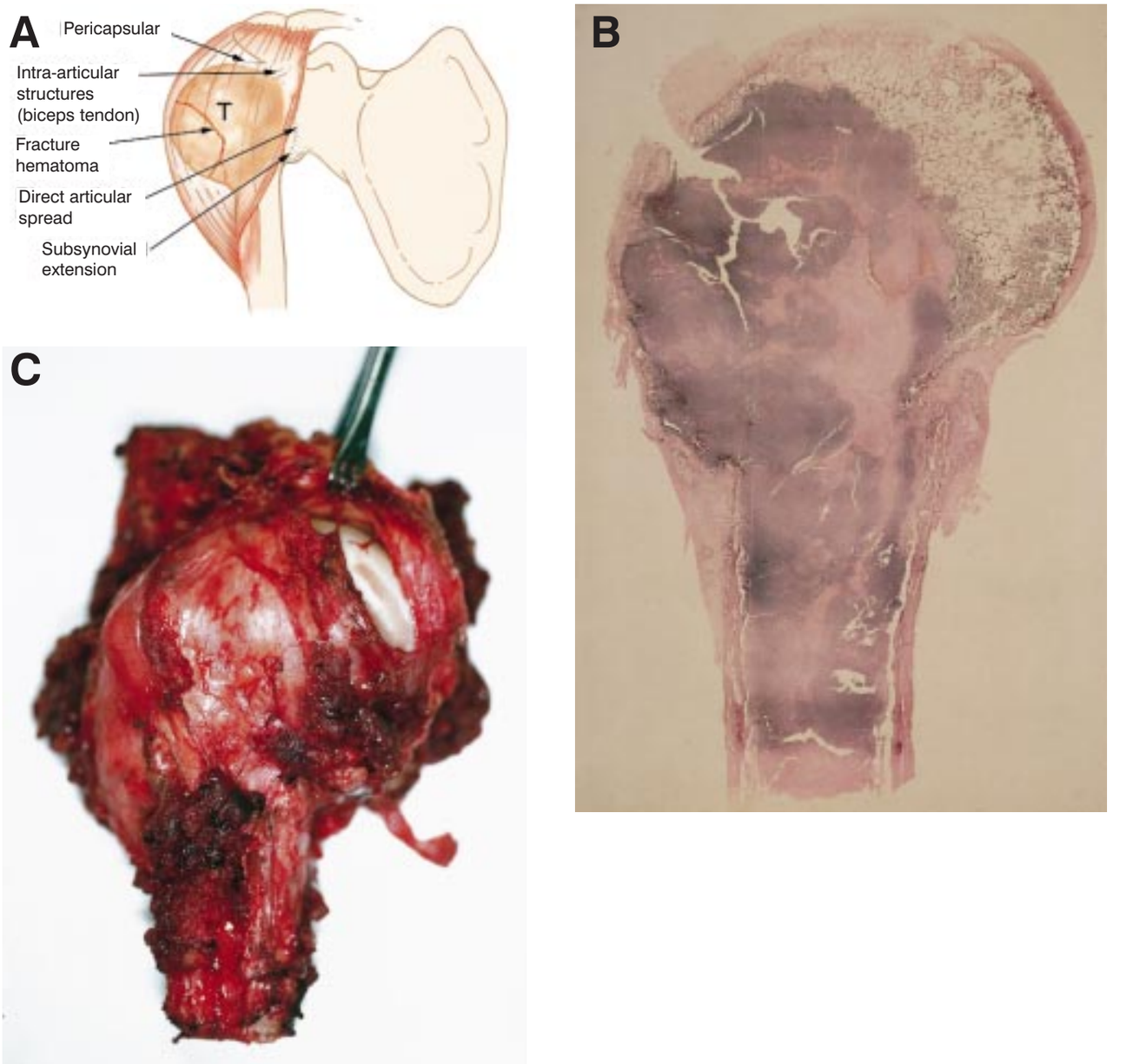

Figure 33.4 *(see also following page)* Biological and anatomic basis for limb-sparing surgery of the proximal humerus. (**A**) The mechanisms of extra-articular involvement of tumors of the proximal humerus (see text). Most high-grade tumors of the proximal humerus are treated by an extra-articular (Type V) resection. Mechanisms of intra-articular joint involvement by high-grade tumors of the proximal humerus: there are five mechanisms of tumor spread from the proximal humerus to the glenohumeral joint or capsule. These mechanisms are direct extension through the articular cartilage, along the capsule and synovium, along an intra-articular structure (biceps tendon), through a fracture hematoma, and direct articular spread. The proximal humerus is at a much higher risk for local recurrence following an intraarticular resection when compared to the local recurrence rate of other major joints. Therefore, it is the author's preference to perform an extraarticular resection for high-grade sarcomas of the proximal humerus (Type V resection). (**B**) Whole mount of a specimen of a high-grade chondrosarcoma of the proximal humerus. Note the tumor involves the humeral head and shaft with some extraosseous extension. (**C**) Surgical specimen following an extra-articular resection for a high-grade osteosarcoma. The capsule can be seen to be opened and the humeral head is visualized. This is the typical resection specimen following a limb-sparing procedure for high-grade tumors of the proximal humerus. (**D**) Gross specimen following a forequarter amputation for a large telangiectatic osteosarcoma of the proximal humerus. There is a huge extraosseous component with massive soft-tissue contamination necessitating an amputation. Today, less than 5% of sarcomas of the proximal humerus require forequarter amputation.

Malawer Chapter 33 22/02/2001 09:15 Page 524

Figure 33.14 D

2. *Magnetic resonance imaging*. MRI is useful to identify intraosseous tumor extent, which is necessary for determining the length of bone resection. It is the best imaging modality for evaluation of soft-tissue tumor involvement, especially around the glenohumeral joint, suprascapular region and chest wall.
3. *Bone scintigraphy*. Bone scintigraphy is used to determine the intraosseous tumor extent and to detect metastases.
4. *Angiography*. Angiography is extremely useful for evaluation of tumor vascularity and tumor response to neoadjuvant chemotherapy. It is also essential for determining the relationship of the brachial vessels to the tumor or the presence of anatomic anomalies. A brachial venogram may also be necessary if there is evidence of distal venous obstruction suggesting a tumor thrombus.

BIOPSY: PROXIMAL HUMERUS

Needle or incisional biopsies of tumors of the proximal humerus should be performed through the anterior one-third of the deltoid muscle, not through the deltopectoral interval. A biopsy through the anterior one-third of the deltoid results in a limited hematoma that is confined by the deltoid muscle. This portion of the muscle and biopsy hematoma are easily removed at the definitive resection. A biopsy through the deltopectoral interval will contaminate the major pectoralis muscle, which is necessary for reconstruction, increase the risk of hematoma spread along the axillary vessels to the chest wall and make a local resection difficult, if not impossible.

If an open biopsy is required, a short longitudinal incision should be made just lateral to the deltopectoral interval. The dissection should be directly into the deltoid muscle and proximal humerus. The bone should be exposed lateral to the long head of the biceps. No flaps should be developed, and the glenohumeral joint should not be entered.

SURGICAL GUIDELINES

It is important to be extremely familiar with shoulder girdle anatomy and axillary and vascular structures.

1. A utilitarian incision is utilized. The anterior component is an extended deltopectoral incision that exposes the pectoralis major muscle, which is then released and retracted towards the chest wall. This exposes the axillary contents and permits exploration and safe dissection of the vascular structures and infraclavicular plexus.
2. An extra-articular resection is performed. Thus, the axillary nerve is identified and transected. The musculocutaneous nerve is identified and preserved. The radial nerve, which crosses the humerus posteriorly at the level of the deltoid insertion, is preserved.
3. Approximately one-half to two-thirds of the humerus is resected.
4. An extra-articular resection is performed by exposing the glenohumeral joint both anteriorly and posteriorly. The scapula is osteotomized medial to the coracoid along with the distal portion of the clavicle. The resected specimen consists of the proximal one-half of the humerus, the glenohumeral joint, and the distal clavicle en-bloc.
5. A modular replacement proximal humeral prosthesis is utilized to reconstruct the skeletal defect.
6. Attention must be paid to the reconstruction of the muscles for soft-tissue coverage of the prosthesis. Static suspension is performed with Dacron tape and the muscle reconstruction is based upon the pectoralis major being sutured to the remaining scapula. The remaining muscles are then tenodesed

Malawer Chapter 33 22/02/2001 09:16 Page 525

to the pectoralis major muscle. This technique permits immediate stability and restores motor power to the upper extremity.

7. An epineural axillary sheath catheter is utilized to control postoperative pain. A 28-gauge chest tube is used for drainage through a Pleurovac.
8. Postoperatively, only a sling is required for 2 weeks.

ENDOPROSTHETIC REPLACEMENT OF THE PROXIMAL HUMERUS

The Modular Replacement System (MRS), which is used for reconstruction of the shoulder girdle, is shown. The results of the MRS are predictable and successful, and the device is used for both intra- and extra-articular resections.

Endoprosthetic reconstruction following tumor resection entails the following steps (Figure 33.5):

- Fixation of the endoprosthesis in the remaining distal humerus.
- Fixation and stabilization of the prosthetic humeral head to the scapula provide a stable shoulder joint.
- Soft-tissue reconstruction to completely cover the prosthesis and optimize postoperative function.

Dual Suspension Technique

A dual suspension (i.e. static and dynamic) technique is utilized to create shoulder stability. The static reconstruction is as follows: drill holes are made in the distal portion of the osteotomized clavicle and through the remaining scapula at the level of the spine. The head of the prosthesis is secured to the remaining portion of the scapula with a 3 mm Dacron tape so that the prosthesis is suspended mediolaterally (for horizontal stability). It is then suspended, using an additional Dacron tape, in a craniocaudal direction from the end of the clavicle (for vertical stability). The dynamic suspension is provided by transfer of the short head of the biceps muscle to the stump of the clavicle (as described in the next section), that allows elbow flexion.

Soft-tissue Reconstruction

The remaining muscle groups are tenodesed to the pectoralis major and osteomized border of the scapula with Dacron tape. This mechanism offers dynamic support, assists in the suspension of the prosthesis, and provides soft tissue coverage. Soft-tissue coverage is essential to cover the prosthesis and prevent skin problems and secondary infections.

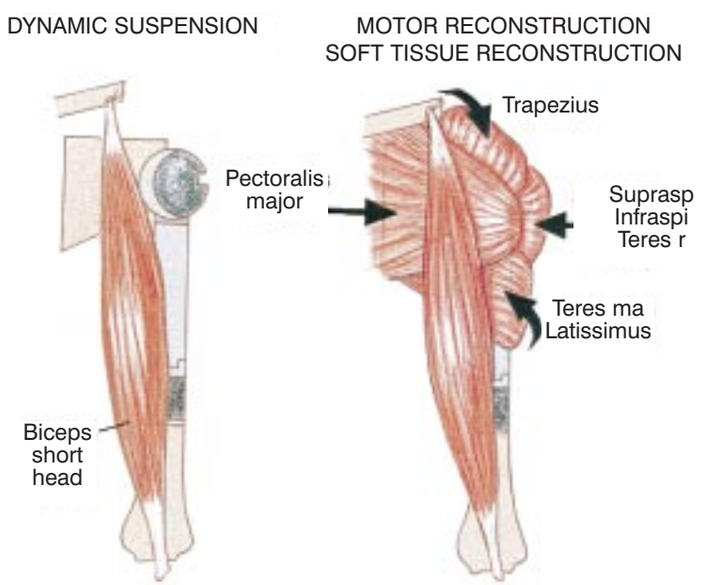

Figure 33.5 Schematic reconstruction of the proximal humerus. There are three major components to the reconstruction of the proximal humerus following an intra- or extra-articular resection. It is important to re-create joint stability and restore muscle power. The author has developed the following techniques of reconstruction (see Figure 33.17):

- Static suspension. The proximal humerus is suspended from the scapula and the clavicle with Dacron tape through drill holes.
- Dynamic suspension is performed by re-creating muscle stability across the new joint. The biceps muscle (conjoin tendon) is transferred to the clavicle. The trapezius is advanced and tenodesed to the pectoralis major muscle.
- Motor reconstruction and soft-tissue coverage. The pectoralis major muscle is sutured to the transected border of the scapula. This covers the prosthesis and re-creates shoulder stability. The trapezius muscle is mobilized and transferred to the pectoralis major muscle in order to regain some lost abduction. The remaining muscles are then tenodesed to the pectoralis major muscle as illustrated. This technique is a reliable method of re-creating shoulder stability and restoring lost motor power.

Malawer Chapter 33 22/02/2001 09:16 Page 526

Intra-articular Resection of the Proximal Humerus (Type I) and Prosthetic Reconstruction

SURGICAL TECHNIQUE

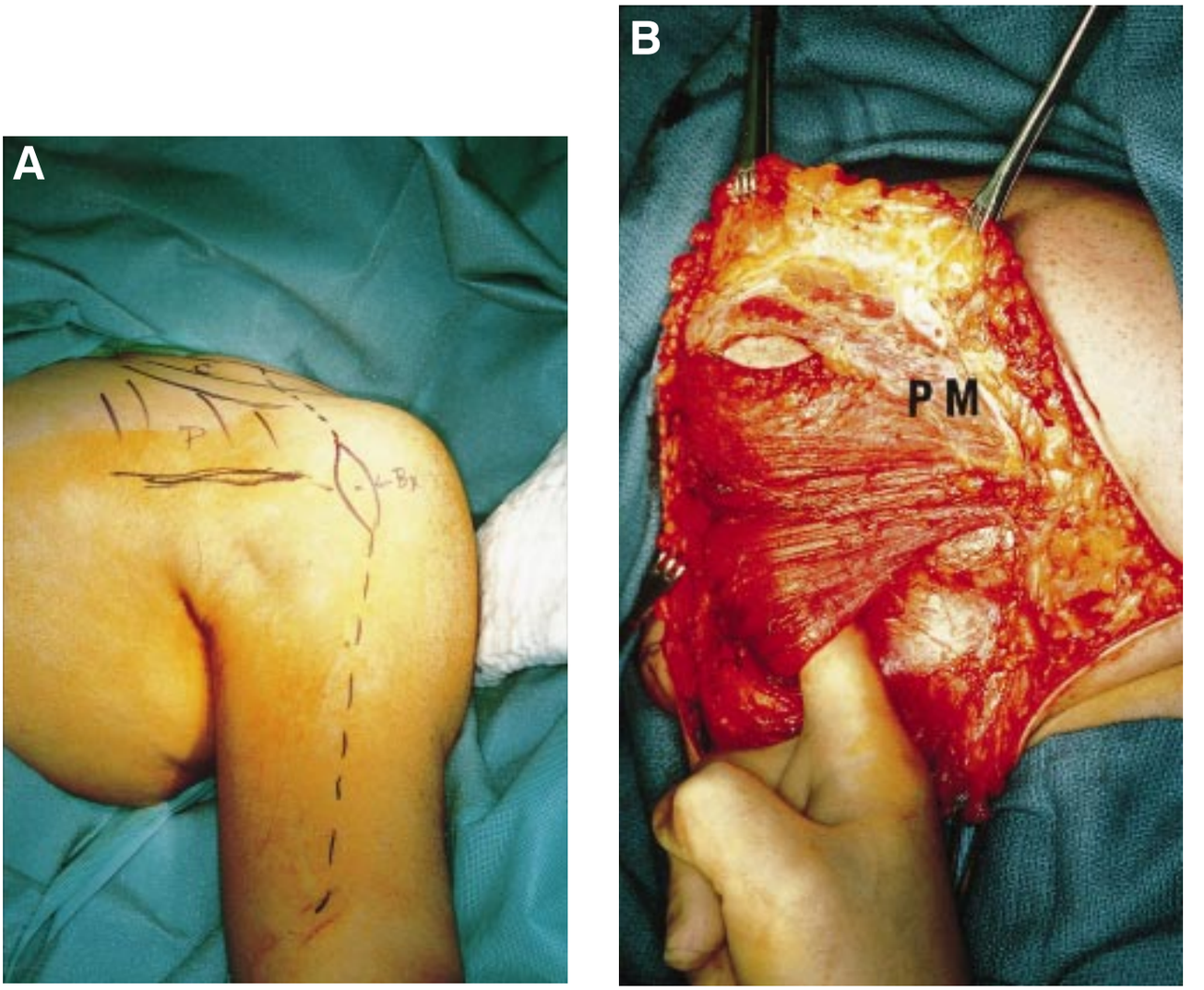

Figure 33.6 *(see also following pages)* Operative photographs of the exposure of an osteosarcoma of the proximal humerus with a modular replacement reconstruction and multiple muscle transfers. (**A**) The anterior incision utilized for resection. Note that the biopsy site is ellipsed out. The cross-hatched areas represent the pectoralis major muscle. (**B**) The deltopectoral interval identifying the biopsy site is seen on top of the deltoid muscle. The surgeon's finger below the pectoralis major (PM) in the axillary space prior to release and mobilization of the muscle. (**C**) The pectoralis major (PM) has been retracted, exposing the deltoid (D) tumor (T) [proximal humerus covered by the subscapularis muscle] and the neurovascular bundle (arrow) that has been protected by a Penrose drain. The axillary artery and nerves are enclosed with the drain. The subscapularis (S) is now easily visualized. (**D**) Photograph showing the surgical defect following resection of the proximal one-half of the humerus. The Penrose drain remains around the vessels. The pectoralis major (P) is shown reflected. The osteotomized scapular border (S) is seen. (**E**) Posterior exposure prior to extra-articular resection. The deltoid muscle (D) attaches to the spine of the scapula posteriorly and the interval for the osteotomy is identified with pick-ups. (**F**) Modular prosthetic reconstruction of the surgical defect. The Dacron tape is utilized for suspension (see text). (**G**) Anterior view of the reconstruction with the modular prosthesis following an extra-articular resection. The Dacron tape is utilized to support the prosthesis and also reattach the pectoralis major muscle (arrow) to the osteotomized section of the scapula to provide for support and coverage of the prosthesis. (**H**) Multiple muscles are rotated and closed over the surgical defect. (PM) Pectoralis major, (B) biceps, (T) triceps, (TR) trapezius, and (I) infraspinatus.

Malawer Chapter 33 22/02/2001 09:16 Page 527

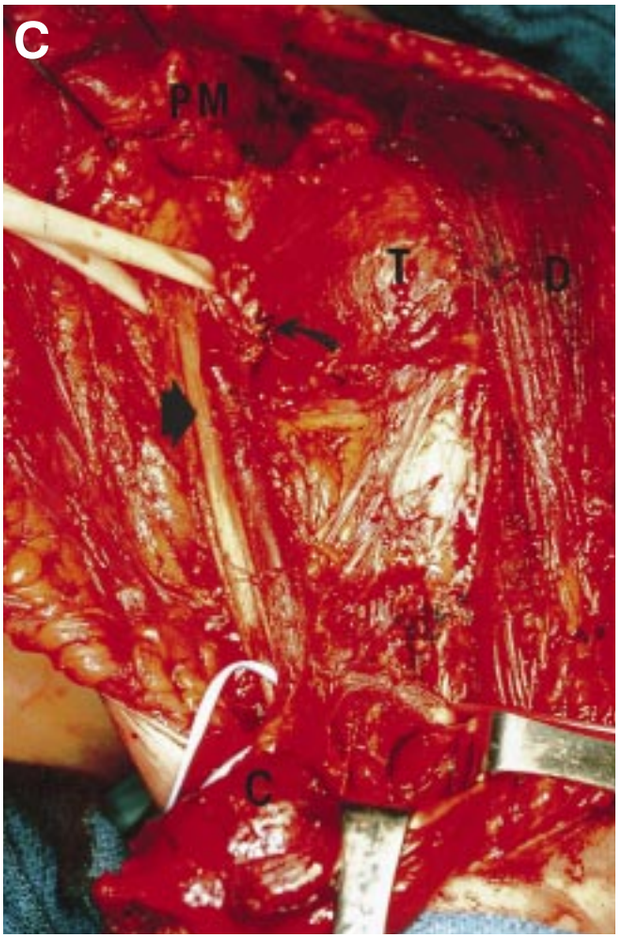

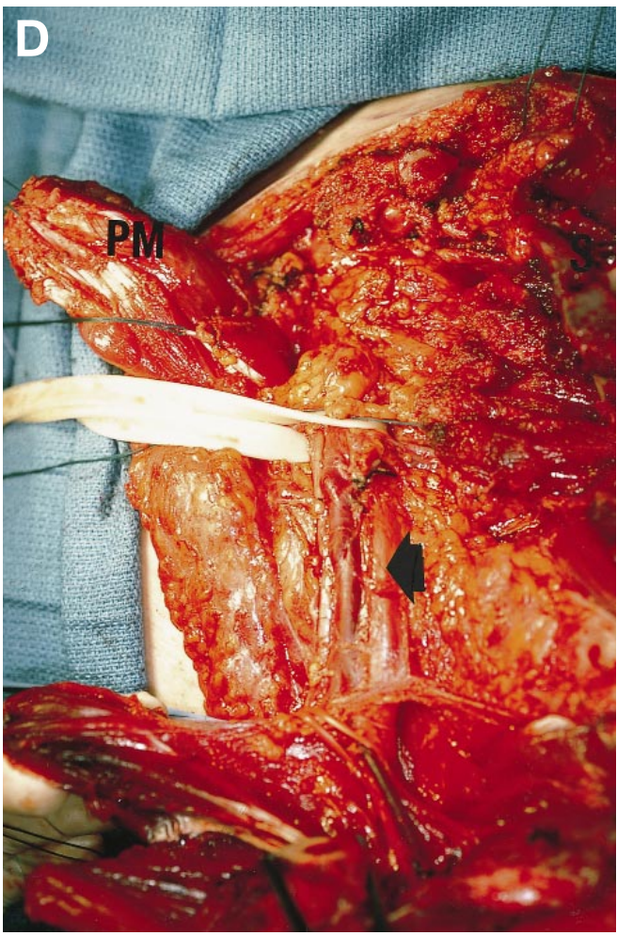

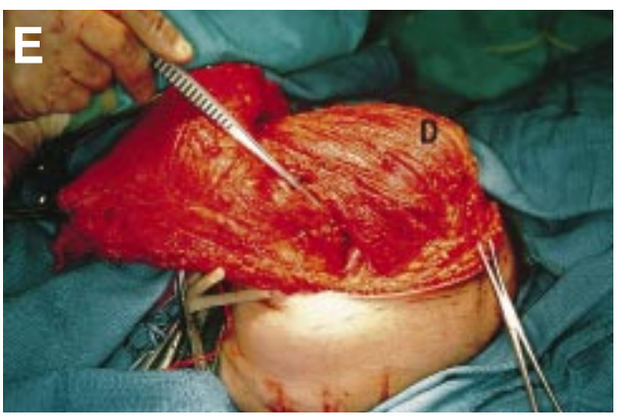

Figure 33.6 C,D,E

Malawer Chapter 33 22/02/2001 09:16 Page 528

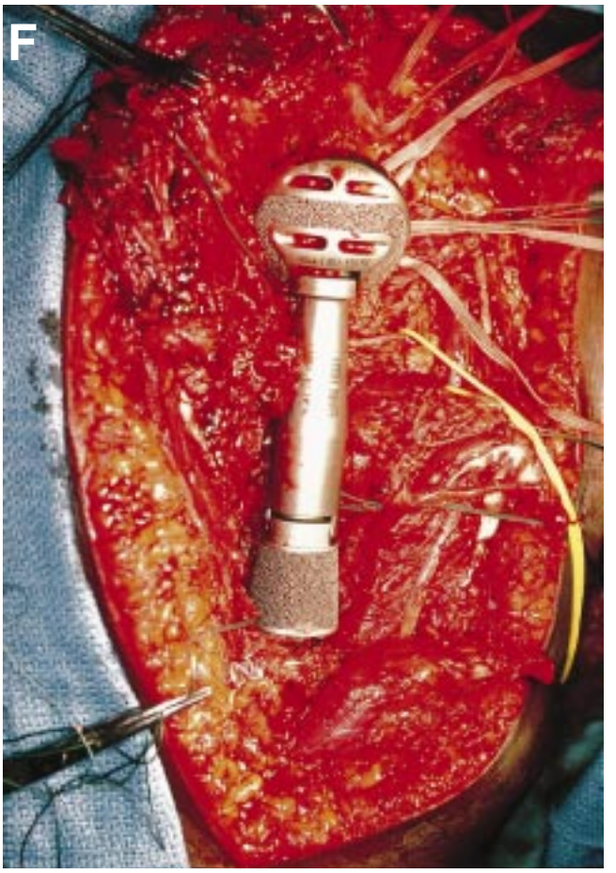

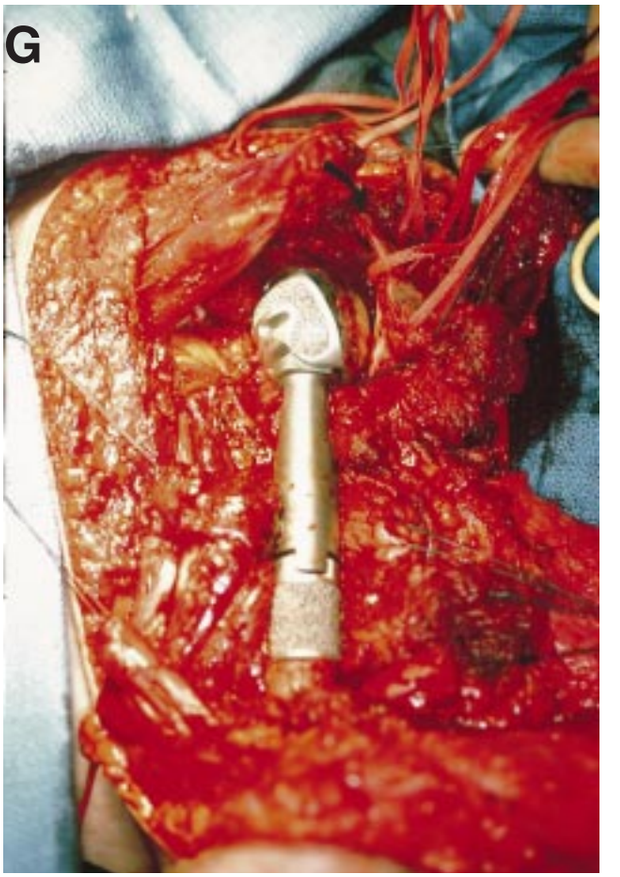

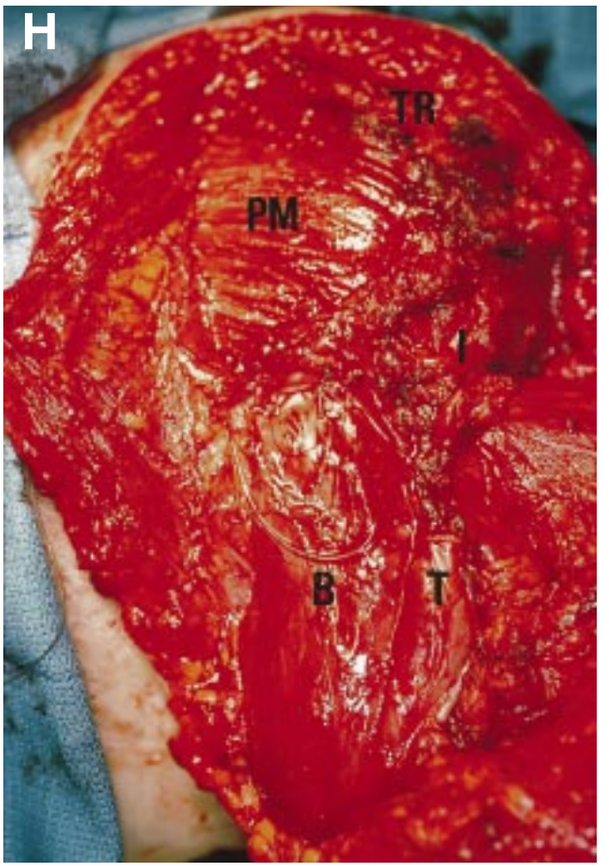

Figure 33.6 F,G,H

Technique for Type V Shoulder Resection

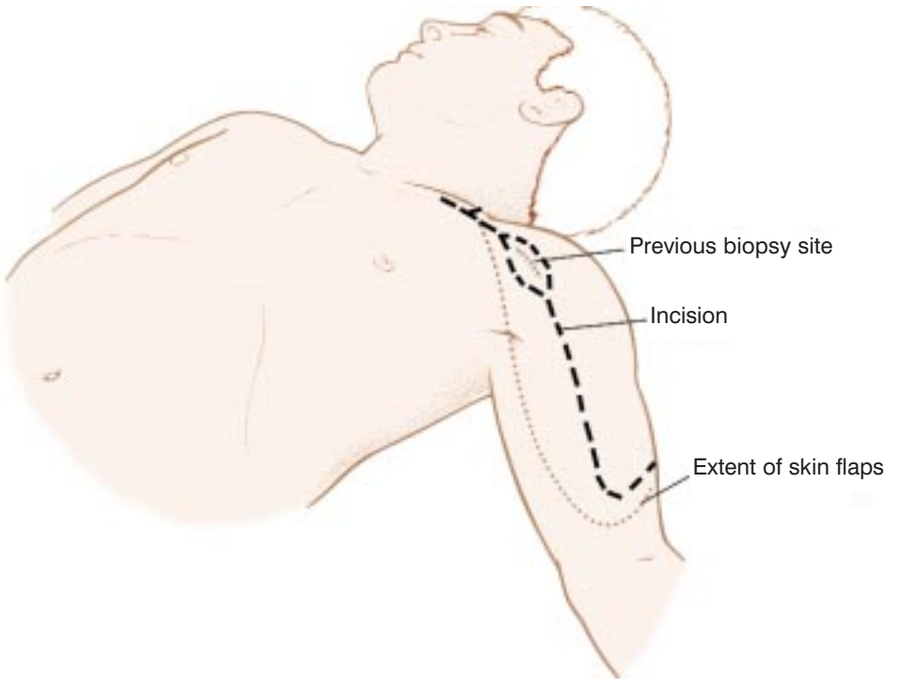

Figure 33.7 Position and incision. Antibiotics are begun preoperatively and continued until suction drains are removed. The patient is placed in an anterolateral position that allows some mobility of the upper torso. A Foley catheter is placed in the bladder and an intravenous line is secured in the opposite extremity. The skin is prepared down to the level of the operating table, to the umbilicus and cranially past the hairline. The incision starts over the junction of the inner and middle thirds of the clavicle. It continues along the deltopectoral groove and then down the arm over the medial border of the biceps muscle. The biopsy site is excised leaving a 3 cm margin of normal skin. The posterior incision is not opened until the anterior dissection is complete.

Figure 33.8 *(see following page)* Exploration of the axilla to determine resectability. The skin is opened through the superficial fascia, but care is taken to preserve the deep fascia of muscles. Anteriorly the skin flap is dissected off the pectoralis major muscle to expose its distal third, and the short head of the biceps muscle is uncovered. The pectoralis major muscle overlying the axilla is dissected free of axillary fat so that its insertion on the humerus can be visualized; this muscle is divided just proximal to its tendinous insertion on the humerus, and the portion of the muscle remaining with the patient is tagged with a suture. The axillary sheath is now identified and the coracoid process visualized. In order to expose the axillary sheath along its full extent, the pectoralis minor short head of the biceps, and coracobrachialis muscles are divided at their insertion on the coracoid process. All proximal muscles are tagged with a suture for their later identification and use in the reconstruction.

Prior to exploration of the neurovascular bundle, the skin flaps are minimally developed. The patient's tumor may be found unsuitable for limb salvage surgery, and more extensive flap dissection at this point would lead to tumor contamination of the anatomic site that would not constitute flaps of a forequarter amputation.

Malawer Chapter 33 22/02/2001 09:16 Page 530

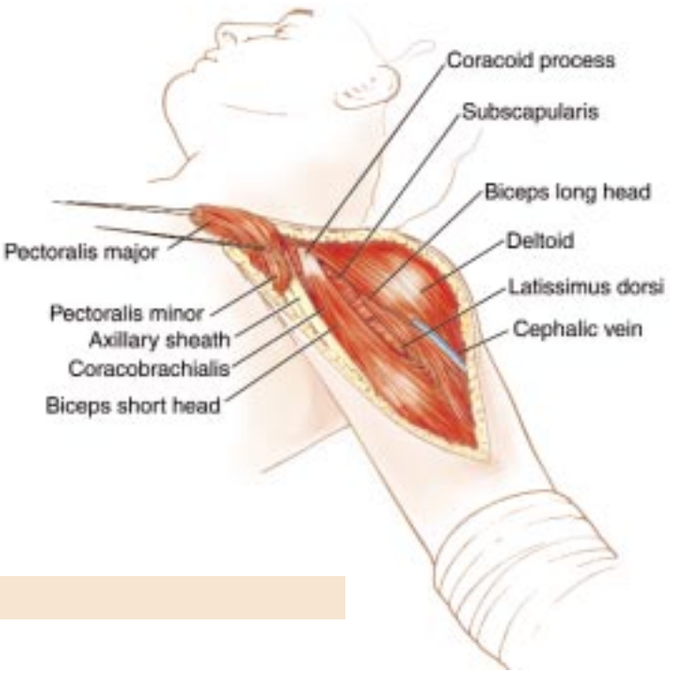

Figure 33.8

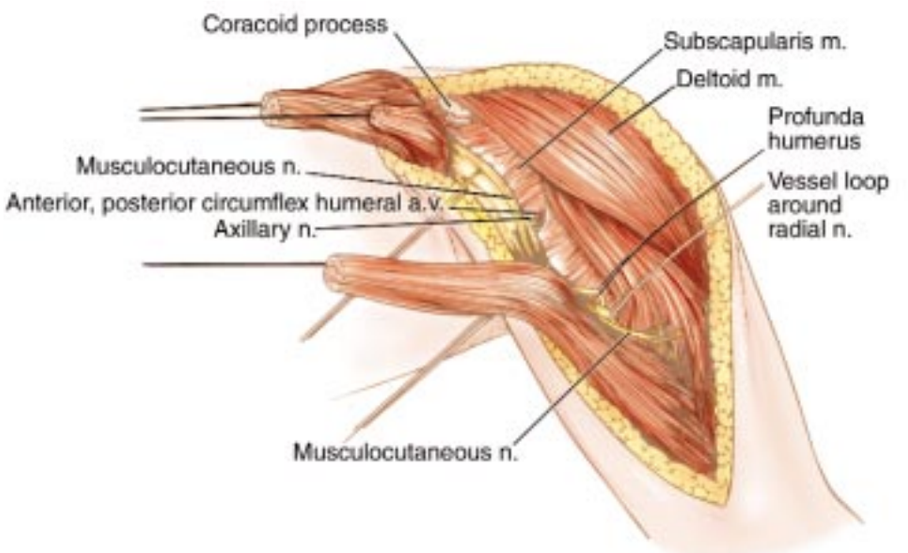

Figure 33.9 Dissection of the neurovascular bundle. Vessel loops are passed around the neurovascular bundle near the proximal and distal ends of the dissection. Medial traction on the neurovascular bundle allows visualization of the axillary nerve, posterior circumflex artery, and anterior circumflex artery. These structures are ligated and then divided. If the neurovascular bundle is found to be free of any extension of the tumor, dissection for the limb salvage procedure proceeds the musculocutaneous nerve is isolated and carefully preserved. Although sacrifice of this nerve is occasionally required to preserve tumor-free margins of resection. Its loss results in lack of elbow flexion following surgery. The deep fascia between the short and long heads of the biceps muscle is divided below the tumor mass to maximally separate the short and long heads of the biceps. This permits easy visualization of the musculocutaneous nerve. The radial nerve is identified at the lower border of the latissimus dorsi muscle passing around and behind the humerus into the triceps muscle group. The profunda brachial artery that accompanies this nerve may be ligated. The radial nerve passes posterior to the humerus in its midportion (spiral groove). To dissect it free of the bone, a finger is passed around the humerus to bluntly move the nerve away from the bone. Likewise the ulnar nerve is traced down the arm: divide the intermuscular septum between biceps and triceps over the nerve to clearly visualize it.

Malawer Chapter 33 22/02/2001 09:16 Page 531

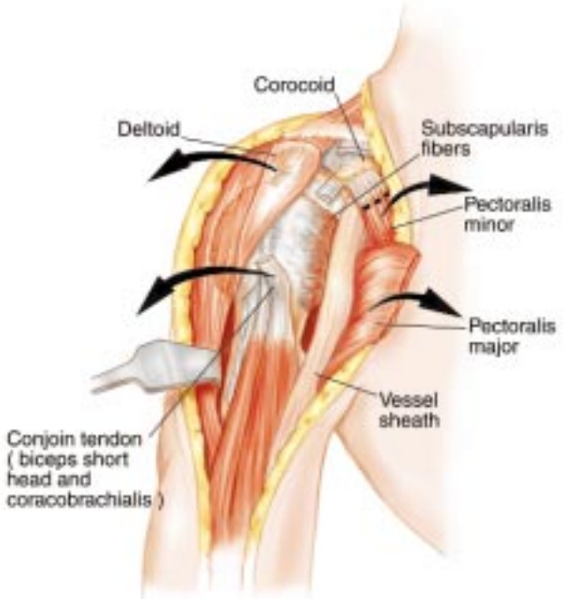

Figure 33.10 Division of muscle groups anteriorly to expose the neck of the scapula. The short and long heads of the biceps are widely separated to expose the humerus. Determine the site for the humeral osteotomy, then transect the long head of the biceps and brachialis muscles at this level. The inferior border of the latissimus dorsi muscle is identified and a fascial incision is made that allows one to pass a finger behind the latissimus dorsi and teres major muscles several centimeters from their insertion into the humerus or scapula. The latissimus dorsi and teres major muscles are transected using electrocautery. External rotation of the humerus exposes the subscapularis muscle, which is transected at the level of the coracoid process. Care must be taken not to enter the joint space. The portions of these muscles that are to remain with the patient are tagged for future reconstruction. By transecting these muscles the anterior portion of the neck of the scapula has been exposed.

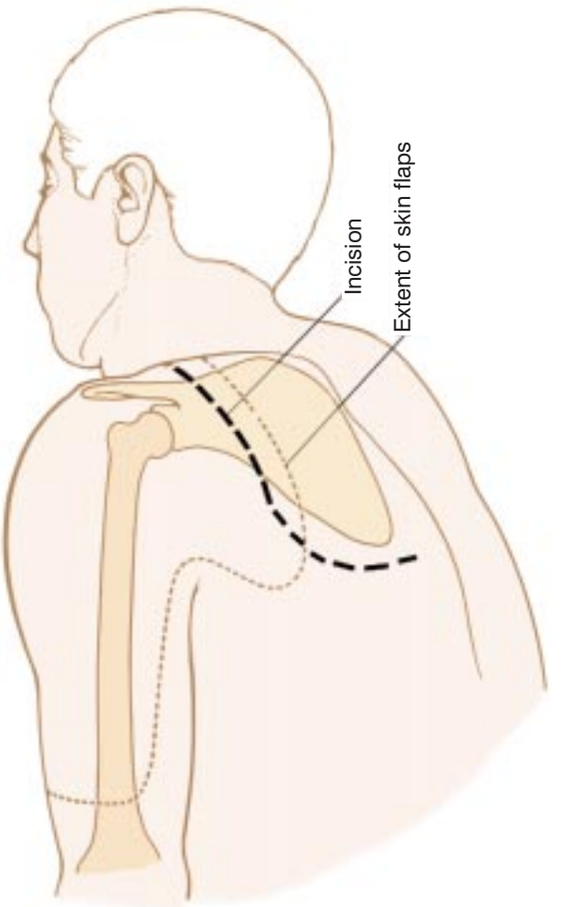

Figure 33.11 Posterior incision and lateral skin flap. The surgeon now changes his orientation from the anterior to the posterior aspect of the patient. Rotation of the table away from the surgeon may allow for better visualization. The posterior incision begins anteriorly over the junction of the middle and lateral thirds of the clavicle. It continues down over the lateral third of the scapula until it passes the lower edge of this bone. A skin flap is developed by dissecting the skin and subcutaneous tissue between the anterior and posterior incisions from the underlying deltoid muscle down to the level of the mid-humerus. If the entire scapula is to be removed, this posterior incision is made longer to allow the skin flap to expose muscle over the entire scapula.

Malawer Chapter 33 22/02/2001 09:16 Page 532

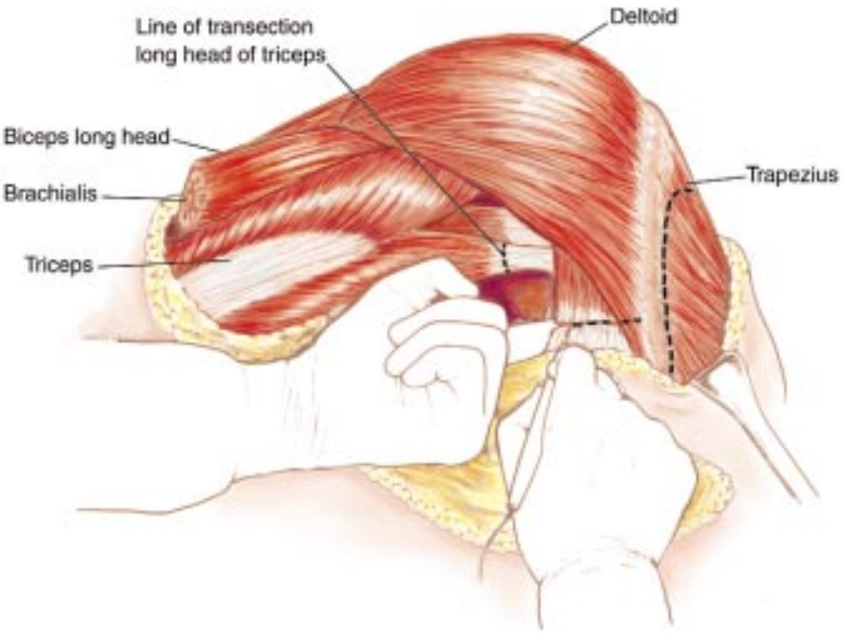

Figure 33.12 Division of muscle groups posteriorly. The thick fascia joining the posterior border of the deltoid muscle to the infraspinatus muscle and scapular spine is divided. The deltoid muscle is left intact as a covering over the tumor mass. The trapezius muscle is transected from its insertion on the scapular spine and acromion. The surgeon's index finger is passed beneath the teres minor up to the area of the planned scapular osteotomy. The supraspinatus, infraspinatus, and teres minor muscles are transected over the neck of the scapula: this allows the plane of transection through the neck of the scapula to be exposed. All transected muscles are tagged proximally. While shielding the radial and ulnar nerves, the triceps muscles are transected at the level selected for the humeral osteotomy.

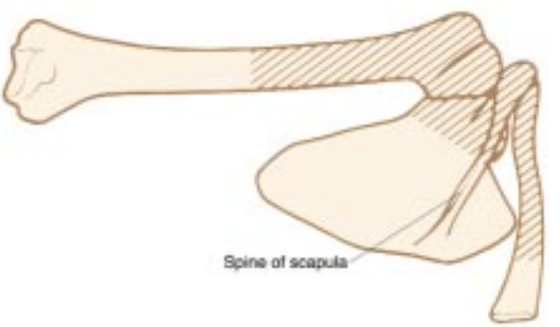

Figure 33.13 Clavicular, scapular, and humeral osteotomies. The clavicle is divided at the junction of its middle and inner one-third. This is usually accomplished with a Gigli saw. The scapula is divided through its surgical neck medial to the coracoid process, also using a Gigli saw. Usually the clavicular and scapular osteotomy are performed prior to the humeral osteotomy.

If the entire scapula is to be resected, the skin flap is raised back to the medial edge of the scapula. After this is accomplished, the rhomboid, levator scapulae and trapezius muscles are divided from their insertions on the scapula. The teres major, teres minor, supraspinatus, infraspinatus and subscapularis muscles need not be divided if a full scapula resection is to be performed.

If the procedure is being performed for a sarcoma of the proximal humerus, the humerus is transected 3–5 cm distal to the tumor as determined by preoperative bone scan. Cryostat sections of tumor margins and touch preparations for cytological examination of the marrow at the site of the osteotomy are obtained. The section of humerus removed is measured and a prosthesis 4–6 cm shorter is selected. Some shortening of the extremity allows better soft-tissue coverage.

Upon removing the specimen, one should note that a generous amount of soft tissue still covers the tumor. The long and lateral heads of the triceps muscle remain on the humerus. The upper portion of the long head of the biceps and the upper portion of the brachialis muscle remain with the specimen. The entire deltoid muscle covers the tumor. The insertions of the supraspinatus, infraspinatus, pectoralis major, latissimus dorsi, teres major nor teres minor, and subscapularis muscles remain covering the tumor and constitute the free margins.

Malawer Chapter 33 22/02/2001 09:16 Page 533

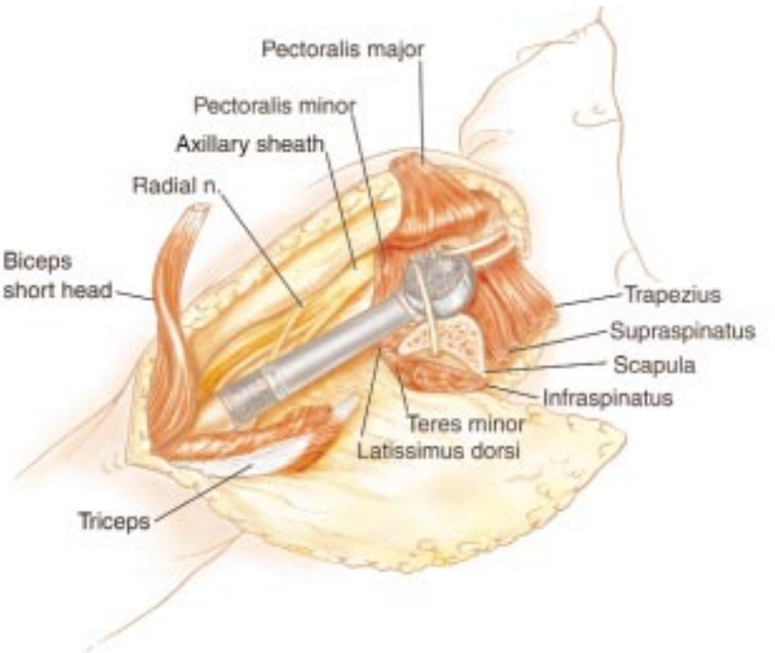

Figure 33.14 Securing the prosthesis. If a prosthesis is to be used, 5–7 cm of distal humerus must be preserved. A power reamer is used to widen the medullary canal of the remaining humerus; it is reamed until it is 1 mm larger than the stem of the prosthesis. The length of the bony specimen is measured so that a prosthesis of appropriate length is used. Methyl methacrylate cement is injected into the medullary canal and the prosthesis is positioned. The head of the prosthesis should be oriented so that it lies anterior to the transected portion of scapula while the arm is in neutral position. The radial nerve should be positioned anterior to the prosthesis so it does not become entrapped between muscle and prosthesis during the reconstruction. Drill holes are made through the scapula at the level of its spine. Drill holes are also made through the distal portion of the transected clavicle. The head of the prosthesis is secured by Dacron tape to the remaining portion of the scapula so that the prosthesis is suspended mediolaterally (horizontal stability). It is suspended in a craniocaudal direction by a second tape from the end of the clavicle (vertical stability). A 3-mm Dacron tape is used.

Figure 33.15 *(see following page)* Reconstruction. The pectoralis minor muscle is sutured to the subscapularis muscle over the neurovascular bundle to protect it from the prosthesis. The pectoralis major muscle is closed over the prosthesis to the cut edge of the scapula and secured with non-absorbable sutures through drill holes. Following this the trapezius, supraspinatus, infraspinatus, and teres minor are secured to the superior and lateral borders of the transected pectoralis major. The teres major and latissimus dorsi muscles are secured to the inferior border of the pectoralis major muscle. The tendinous portion of the short head of the biceps is secured anteriorly under appropriate tension to the remaining clavicle. The long head of the biceps and brachialis muscles are sutured to the short head of the biceps muscle under appropriate tension so that these two muscles can work through the short biceps tendon. The remaining triceps muscle is secured anteriorly along the lateral border of the biceps to cover the lower and lateral portion of the shaft of the prosthesis. Ideally when the proximal and distal muscular reconstruction is complete the prosthesis is covered in its entirety by muscle.

Malawer Chapter 33 22/02/2001 09:16 Page 534

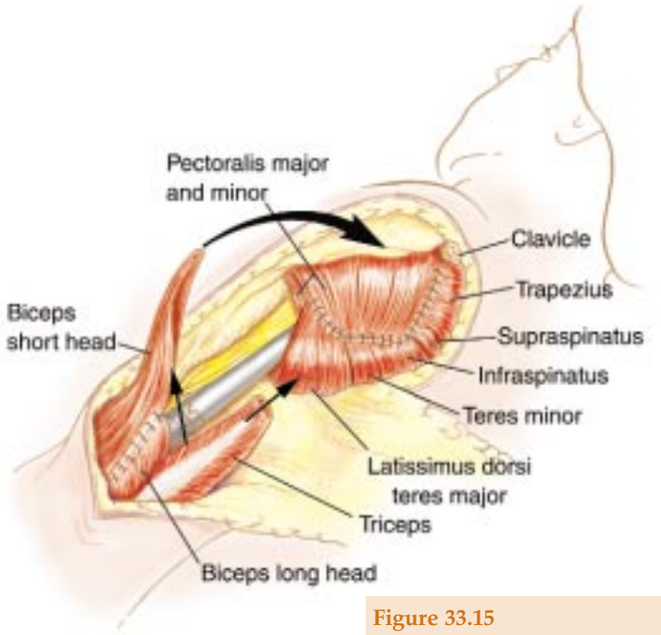

Figure 33.15

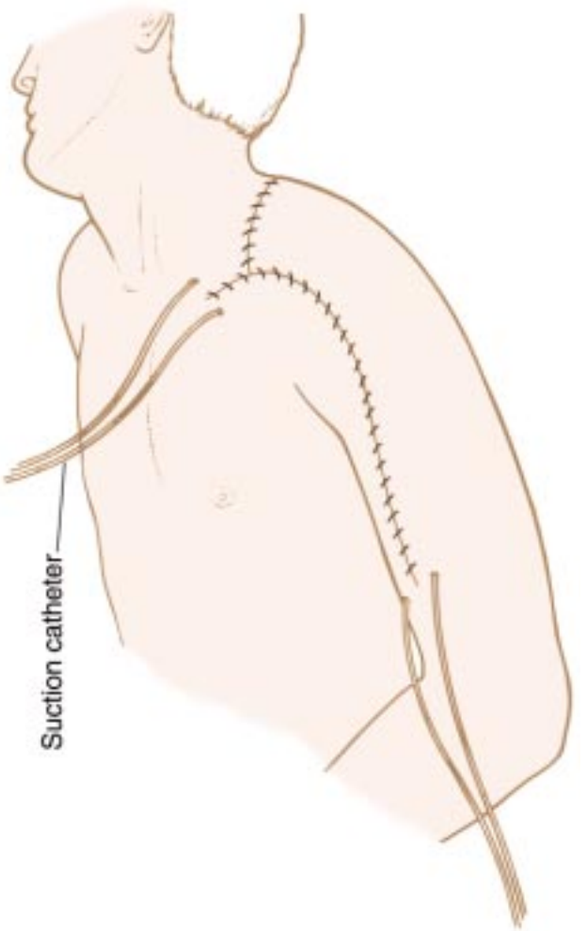

Figure 33.16 Closure. Large-bore suction catheter drainage is secured. The superficial fascia is closed with absorbable suture and the skin is closed with clips. Povidoiedine ointment is applied to the incision along with a dry sterile dressing. A sling and swathe are applied in the operating room.

Malawer Chapter 33 22/02/2001 09:16 Page 535

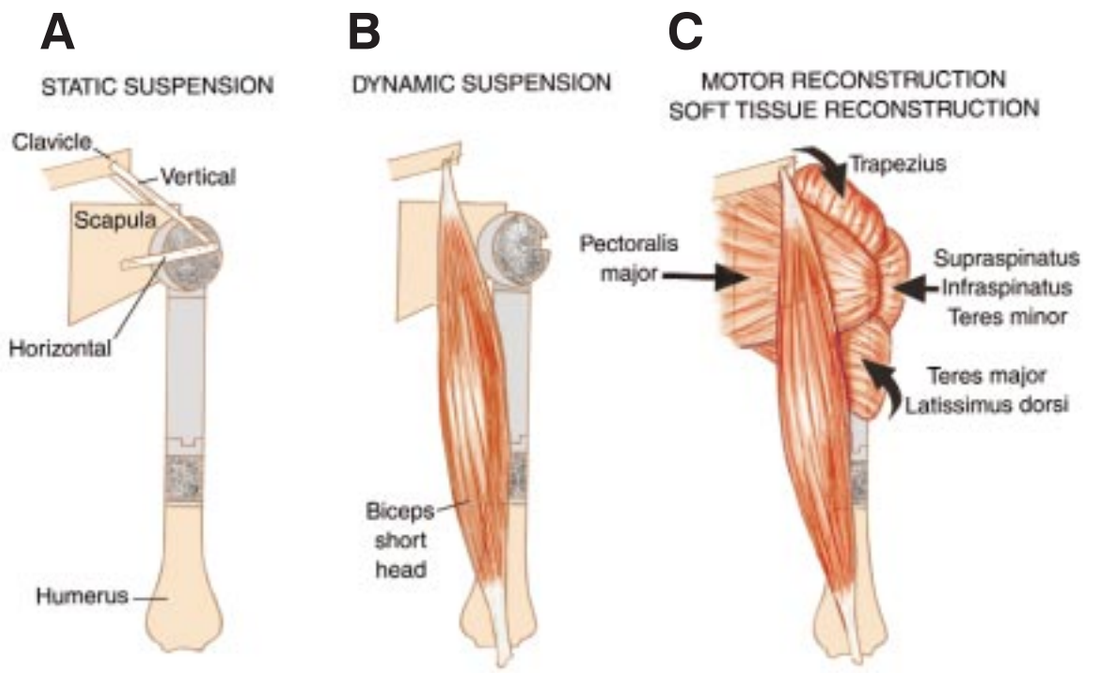

Figure 33.17 (**A**) Static suspension of the prosthesis. The interposition prosthesis is secured horizontally by Dacron tape placed through drill holes in the scapula. Vertical stability is achieved by passing tape through drill holes in the end of the clavicle. (**B**) Dynamic suspension of the prosthesis. Elbow flexion is preserved by transferring the short head of the biceps muscle to the end of the clavicle. (**C**) Motor reconstruction and soft tissue coverage. The pectoralis major muscle is secured to the scapula to provide forward flexion of the shoulder. Extension of the shoulder occurs through transfer of the trapezius, teres major, and latissimus dorsi muscles.

Figure 33.18 *(see following page)* Intraoperative photographs of an intra-articular resection of the proximal humerus with reconstruction using a Gore-Tex® graft (Type IA resection). (**A**) Intraoperative defect following resection of a large renal cell carcinoma of the proximal humerus. The axillary nerve and deltoid muscle must be preserved if an intra-articular resection is to be performed (small arrow shows axillary nerve; note its course around the glenoid, entering the deltoid posteriorly; D shows the deltoid muscle). The pectoralis major (P) has been detached and retracted, exposing the axillary vessels and nerves. The neurovascular bundle must be carefully dissected away from the large soft-tissue component of the tumor prior to resection. It is essential to preserve the musculocutaneous nerve (MC) as well as the radial nerve (R) and the axillary nerve (small arrow). Exposure is facilitated by detaching the pectoralis major and reflecting it toward the chest wall. The pectoralis minor and the conjoin tendon must be released from the coracoid. The neurovascular sheath is found in the loose axillary fat and is dissected. (**B**) Gross specimen following resection. Note the extraosseous tumor component (large arrow) which is typical of renal cell carcinoma metastases to the bone. The proximal humerus is a common site for metastatic renal cell carcinomas. (**C**) Capsular reconstruction with Gore-Tex® graft. Note the proximity of the neurovascular structures. The Gore-Tex® is first sutured to the remaining glenoid labrum with Dacron tape (**D**). The humeral head of the prosthesis is then inserted into the Gore-Tex® (new capsule) and held closely to the glenoid and then it is sutured to the holes in the prosthesis with Dacron tape. The remaining capsule is sutured to the Gore-Tex® "capsule". The redundant Gore-Tex® is then trimmed and sutured with Ethibond sutures to close the new pseudocapsule. We utilize Gore-Tex® reconstruction even if there are remaining capsular structures. This reinforces the capsule rotator cuff and prevents subluxation and dislocation.

Malawer Chapter 33 22/02/2001 09:16 Page 536

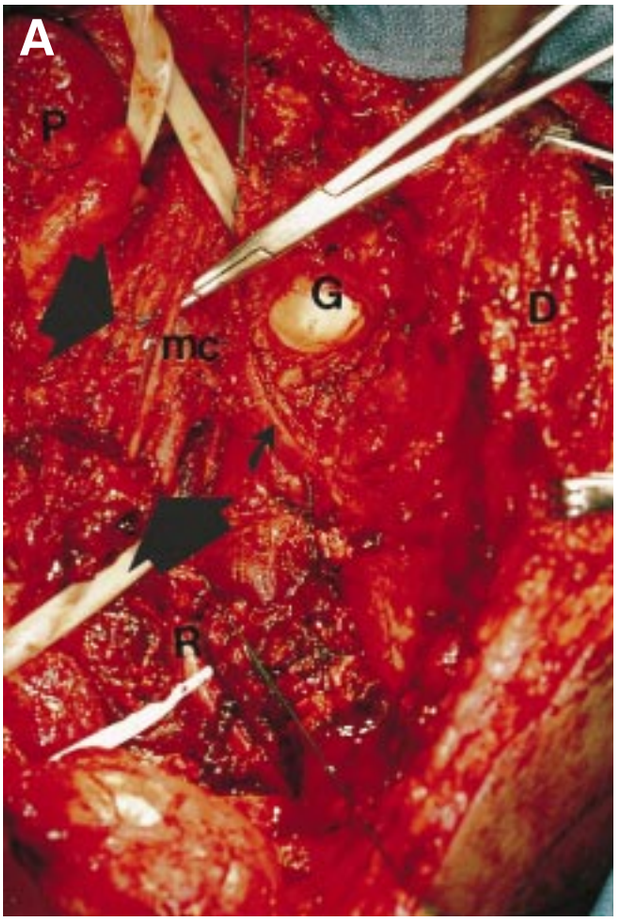

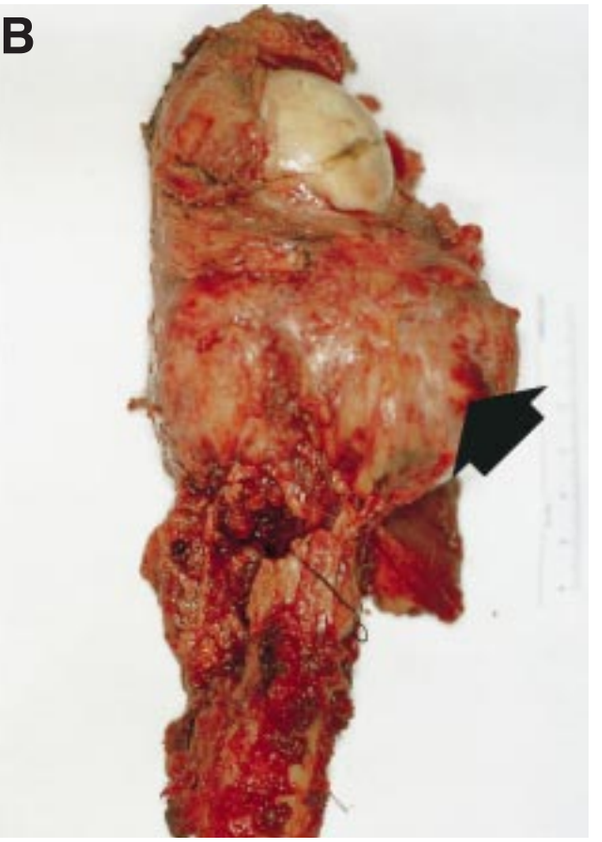

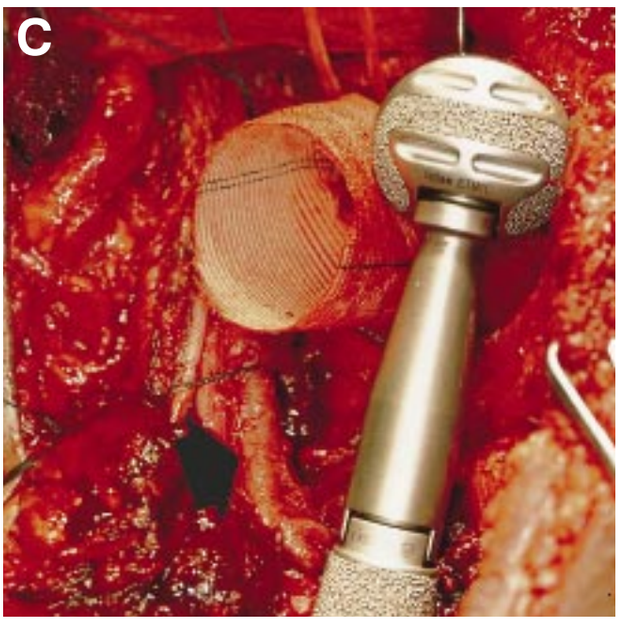

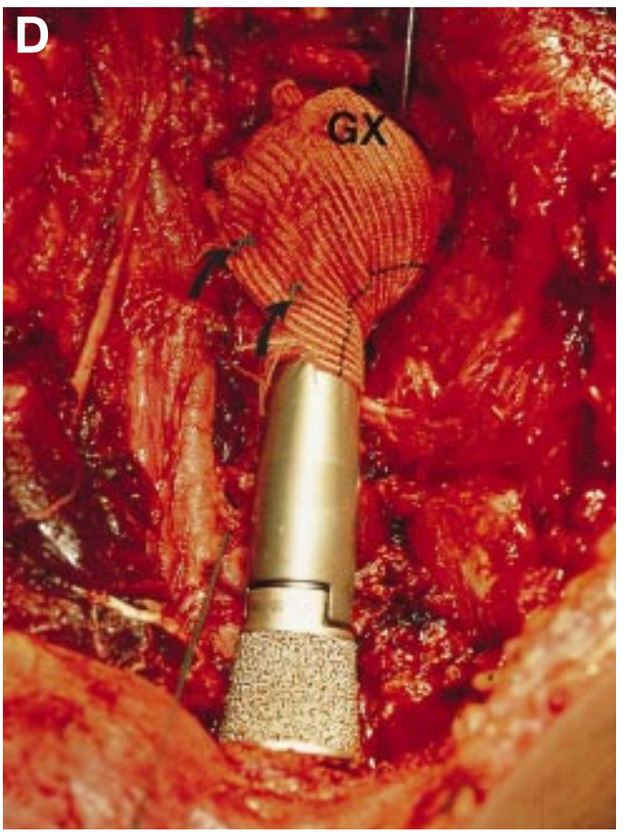

Figure 33.18 A–D

Malawer Chapter 33 22/02/2001 09:16 Page 537

Type I Resection

Intra-articular resection of the proximal humerus is indicated for low-grade sarcomas or high-grade sarcomas confined to the bone without extraosseous extension (Stage IIA). The abductor mechanism and axillary nerve are usually preserved. This procedure is not recommended for high-grade sarcomas with soft-tissue extension. The prosthesis is suspended from the glenoid with Gore-Tex™ graft that is reinforced by any remaining capsule (Figure 33.19).

- Anterior utilitarian shoulder incision is not required. The posterior component is not used.
- The axillary nerve is explored early and preserved. If there is tumor extension to the nerve, then the procedure is converted to a Type V resection.
- The humeral prosthesis is suspended from the glenoid labrum with 32 mm Gore-Tex. The remaining capsule is sutured to the new Gort-Tex capsule. This

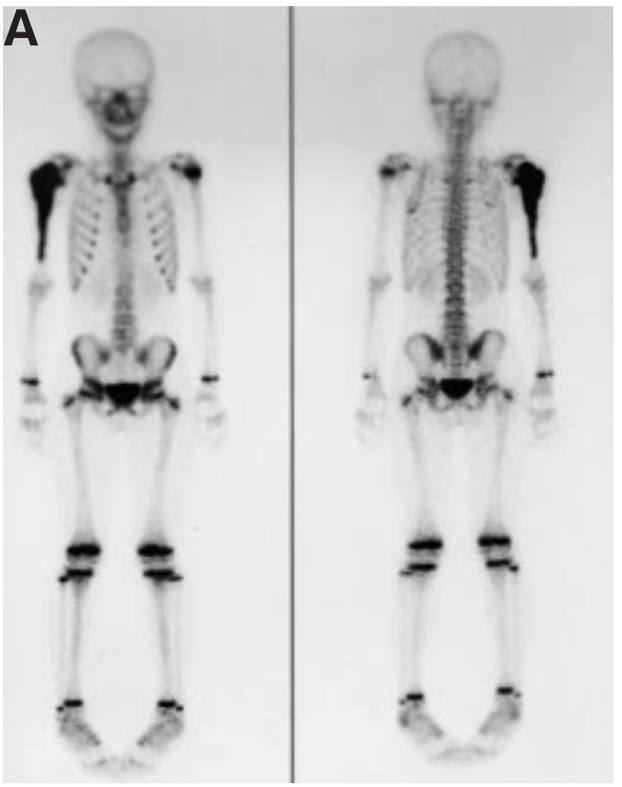

Figure 33.19 *(see also following page)* Osteosarcoma involving almost the entire humerus, necessitating a total humeral replacement as a limb-sparing procedure in lieu of a forequarter amputation. (**A**) Bone scan showing 90% of the humerus is involved by a high-grade osteosarcoma. (**B**) Plain radiograph following induction chemotherapy showing a large extraosseous osteosarcoma of the proximal humerus with a soft-tissue component that has ossified secondary to chemotherapy. Note the reossification of the tumor, which was unexpected in the distal humerus, just above the elbow (arrow.) (**C**) Plain radiograph of a total humeral replacement following a Type V shoulder girdle resection combined with a distal humeral resection. Note a fixed hinge prosthesis was utilized. (**D**) Composite photograph of a total humeral resection with a large proximal soft-tissue component reconstructed with an expandable prosthesis due to the patient's immature skeleton. Either an articulated or non-articulated elbow component can be utilized depending on the patient's age. It is important to reconstruct the elbow capsule and tenodese the muscles to the capsule if a non-hinged prosthesis is utilized.

Malawer Chapter 33 22/02/2001 09:16 Page 538

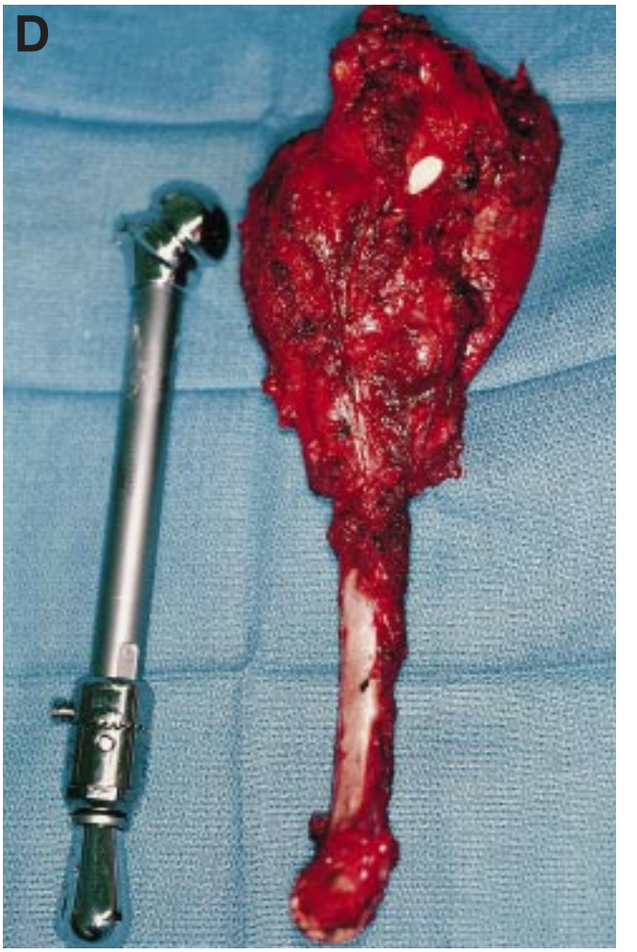

Figure 33.19 C,D

avoids glenohumeral joint subluxation and dislocation.

Total Humeral Resection and Prosthetic Reconstruction

Total humeral replacement is unusual but is indicated when there is tumor involvement of a large portion of the diaphysis, such as in Ewing's sarcoma, or when an extremely short segment of distal humerus remains following adequate tumor resection. The surgical technique is a combination of that used for the proximal humerus and distal humerus resections. Reconstruction provides stability of both shoulder and elbow joints (Figure 33.20).

Exposure and Extension of Type V Procedure

The surgical approach is similar to that used for a Type V resection (i.e. anterior utilitarian approach) but requires additional distal exposure and identification and mobilization of the brachial artery and vein and the radial, ulnar, and median nerves. The incision and exposure are continued down the anteromedial aspect of the arm, across the antecubital fossa and, if necessary, down the anterior aspect of the forearm. The brachial vessels, along with the median and ulnar nerves, are identified medially in the arm. The medial intermuscular septum is transected to allow further dissection and mobilization of the ulnar nerve so that it can be retracted medially with the brachial vessels and median nerve. The biceps is retracted medially with the neurovascular bundle. The radial nerve is identified and passes around the humerus and into the interval between the brachialis and brachioradialis, and continues into the forearm.

The pronator teres and common flexor origins are transected medially, and the brachioradialis, extensor carpi radialis longus, and common extensor origins are released laterally to expose the distal humerus. A small cuff of muscle is left around the tumor as needed. The medial triceps muscle is usually resected with the tumor, but the lateral and long heads are retained. The

Malawer Chapter 33 22/02/2001 09:16 Page 539

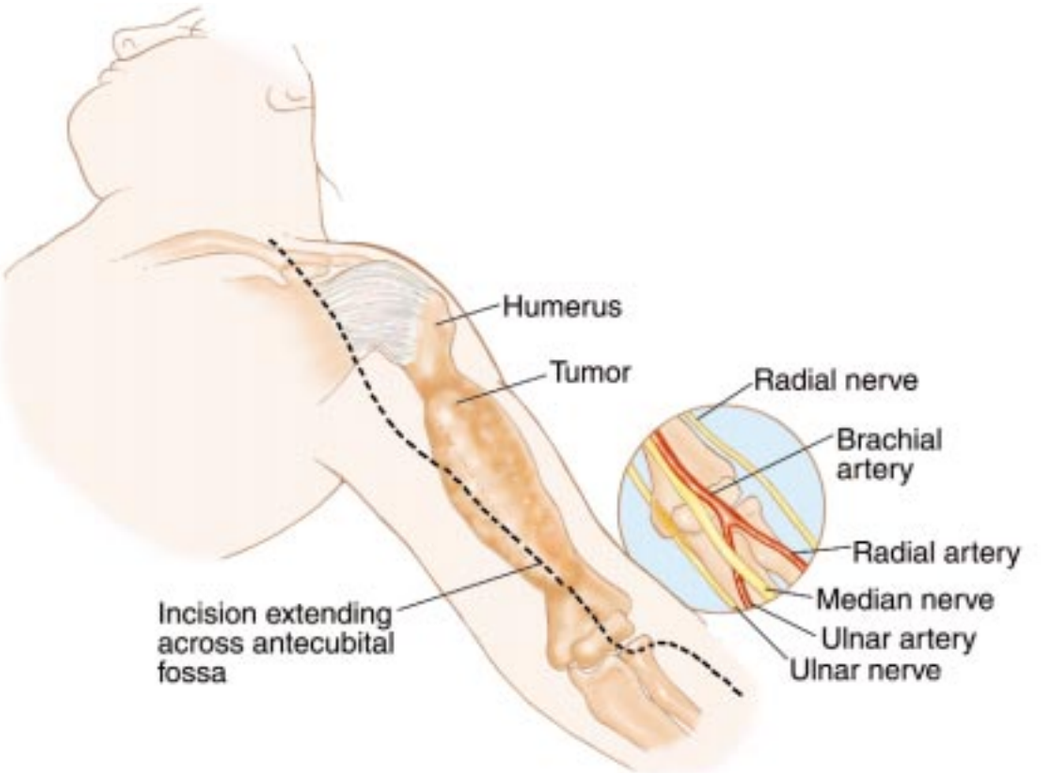

Figure 33.20 Schematic diagram of a total humeral resection. The resection of the proximal 90% of the humerus is similar to the Type V resection seen in Figure 7–18. The incision is extended along the elbow joint anteriorly and the brachial vessels, ulnar nerve, and median nerve are identified and retracted. The prosthesis is then reconstructed proximally, as above the elbow joint is either an articulating or non-articulating prosthesis based on the patient's age. It is essential to reconstruct the capsule and the adjacent muscles to the elbow joint for stability. A posterior splint is utilized postoperatively for 2–3 weeks to allow for stability.

triceps tendon is kept attached to the olecranon. The olecranon is not osteotomized. The elbow joint is opened anteriorly and the capsule released circumferentially. The humeroulnar and radiohumeral joints are then disarticulated.

Prosthetic Reconstruction

Reconstruction of the total humerus is similar to that of the proximal humerus. Distally, an ulnar endoprosthetic component with an intramedullary stem is cemented, with the olecranon left intact. Several articulating elbow devices are available.

Muscle Reconstruction

The reconstruction technique is similar to that used for the proximal humerus, with the addition of distal soft-tissue and joint capsule reconstruction. The brachioradialis, pronator teres, and flexor carpi radialis muscles are sutured to the remaining biceps and triceps muscles to secure soft tissue around the flared distal portion of the humeral endoprosthesis. The remaining muscles are closed in layers in an attempt to cover the entire prosthesis.

Postoperative Management

A posterior splint is used to protect the elbow reconstruction for 7–10 days. The surgical incision and wounds are examined on the fourth to fifth postoperative day.

DISCUSSION

High-grade sarcomas of the shoulder girdle have been treated traditionally by interscapulothoracic amputation.

Non-ablative extirpation has been rare. This chapter contains a complete description of the technique for a modified Tikhoff–Linberg procedure in patients with sarcomas of the proximal humerus. Also, modifications of the procedure for tumors at other anatomic sites have been utilized. Proximal humeral lesions require resection of about two-thirds of the humerus.

The technique of resection and reconstruction requires a thorough knowledge of the regional anatomy and technique of musculoskeletal reconstruction. Essential aspects of the treatment plan should be emphasized. The initial biopsy should be performed through the anterior portion of the deltoid muscle for a lesion of the proximal humerus. The deltopectoral interval should not be utilized, because biopsy here would contaminate the deltopectoral fascia, the subscapularis, and pectoralis major muscles, and would jeopardize the ability to perform an adequate resection through uninvolved tissue planes. For the definitive resection the initial incision extends along the medial aspect of the biceps muscle, divides the pectoralis major and exposes the neurovascular structures, thereby enabling the surgeon to determine resectability early in the dissection. This incision does not jeopardize construction of an anterior skin flap in patients who will require forequarter amputation.

The length of bone resection is determined preoperatively from a bone scan and MRI. To avoid a positive margin at the site of humeral transection the distal osteotomy is performed 3–5 cm distal to the area of abnormality on the scan. Segmental reconstruction of the resultant humeral defect is necessary to create shoulder stability. The authors do not leave a flail extremity. Reconstruction is necessary to maintain length of the arm and to create a fulcrum for elbow flexion. We recommend a custom or modular prosthesis. Alternatively, other surgeons utilize autografts (usually fibulas) or allografts as spacers in obtaining an arthrodesis. We do not recommend osteoarticular allografts or intraarticular resections for high-grade bone sarcomas; those techniques were developed during the 1960s and 1970s. Superior results are routinely obtained with modular prosthetic replacements combined with reconstruction of the soft tissues. The key to success is reconstruction of the stability of the joint and soft-tissue coverage of the prosthesis.

AXILLARY TUMORS

Introduction

Several types of malignant tumors may involve the axillary space and may require surgical resection. Primary sarcomas occur within the muscles (pectoralis major, latissimus dorsi, teres major, and subscapularis muscles) that make up the borders of the axillary space. Rarely do they develop within the axillary fat itself. More commonly, large metastatic deposits to the regional lymph nodes create large, matted masses that may require resection. The most common of these are metastatic melanoma and recurrent breast carcinoma. In addition, there are primary tumors that arise from the brachial plexus, either the nerves or the vessels. These include leiomyosarcomas of the axillary vein and neurofibrosarcomas of the adjacent nerves. Large tumors of the proximal humerus or scapula often extend into the axillary space and require the same imaging evaluation and surgical approach as do tumors in other anatomic sites.

The key to adequate and safe surgical resection of axillary tumors is the complete visualization and mobilization of the infraclavicular portion of the brachial plexus; the axillary artery, vein and the cords that surround them. In general, imaging studies of the axillary space are not reliable in determining vascular or nerve sheath involvement. Multiple imaging studies are required, (Figures 33.21–33.23), but the decision to proceed with a limb-sparing surgery is based on the intraoperative findings at the time of exploration.

Gross tumor involvement of the brachial plexus and/or the major vessels is an indication for amputation or for the need to abandon the attempt for resection. Other contraindications to axillary space resection include involvement of the neurovascular bundle and involvement of the adjacent chest wall. The technique of axillary space exploration via the transpectoralis approach described here has been developed by the authors, and has been found to be the most useful in this determination and surgical approach.

Unique Anatomic Considerations

Anatomic Borders

The axilla is a pyramid-shaped space between the chest wall and the arm. The apex of the pyramid superiorly is formed by the junction of the clavicle and the first rib. This apex is approximately 1–2 cm medial to the coracoid process. The anterior wall of the axilla is formed by the pectoralis major muscle, and the posterior wall is formed by the subscapularis, teres major, and latissimus dorsi muscles. The chest wall and the serratus anterior muscle form the medial wall of the triangle. The humeral shaft covered by the muscle fibers of the coracobrachialis and the short head of the biceps define the lateral wall. The axilla is triangle-shaped when seen from both the coronal and axial views.

The most significant structures of the axillary space are the axillary artery and vein, which are surrounded by the cords of the brachial plexus as they enter from

Malawer Chapter 33 22/02/2001 09:16 Page 541

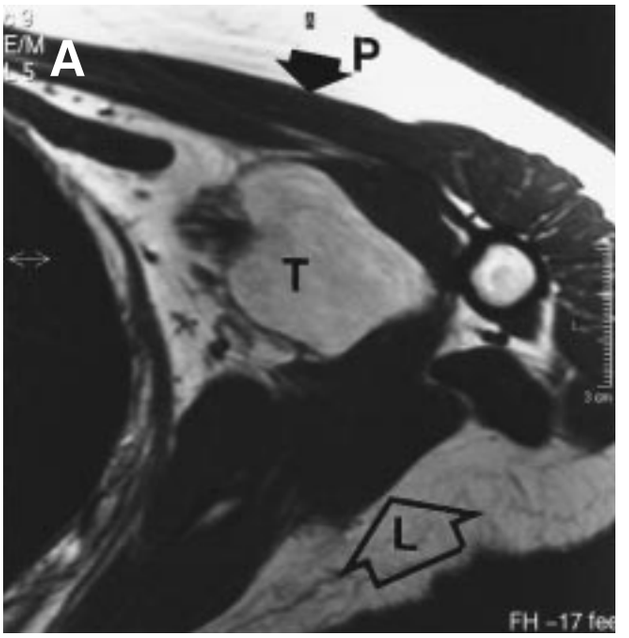

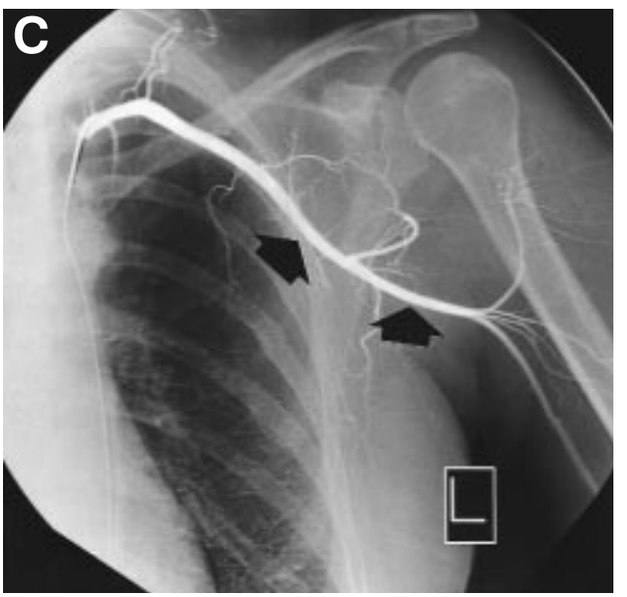

Figure 33.21 Liposarcoma (low grade) of the axillary space. (**A**) MRI of the left axilla demonstrates a large tumor (T) filling the axillary space. The axillary space is formed by the pectoralis major muscle (P) anteriorly; the latissimus dorsi and the teres major muscles form the posterior border. This is a good demonstration of a primary tumor arising within the axillary space. (**B**) Coronal MRI. This T1-weighted image demonstrates the tumor (T) filling up the entire axillary space from proximal to the coracoid process (level 1) to the inferior margin. The neurovascular sheath (solid arrow) is displaced inferiorly. (**C**) AP angiogram corresponding to the coronal MRI demonstrates marked displacement of the axillary artery. This is an early arterial phase and demonstrates minimal vascularity.

the apex and pass through the axillary space medial to the coracoid to the medial aspect along the humeral shaft. This space is filled with a fair amount of fat. The lymphatics and lymph nodes follow the axillary vessels. The space is bounded anteriorly by the deep clavicular pectoralis fascia that arises from the clavicle and covers the deep fat below the pectoralis major muscle. Inferiorly, the fascia wraps around the base of the axilla. It is extremely important that the surgeon identify this layer before entering the deeper layers.

Pectoralis Major and Conjoined Tendon Muscles

There are two major muscles that form the gateway to the axillary space and that lie just below the clavicular–

Malawer Chapter 33 22/02/2001 09:17 Page 542

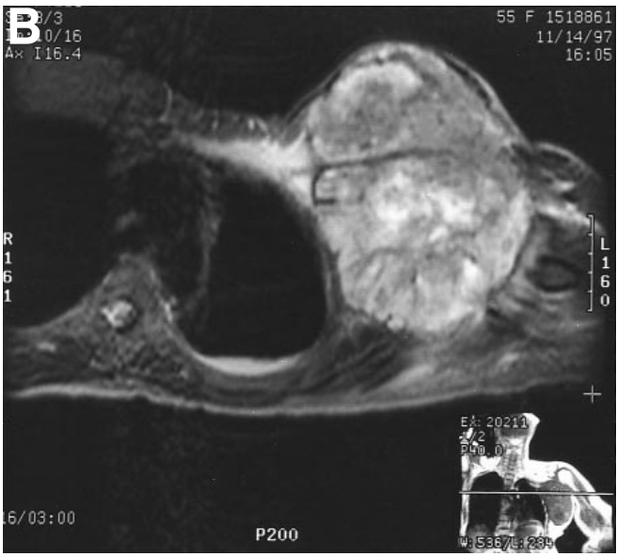

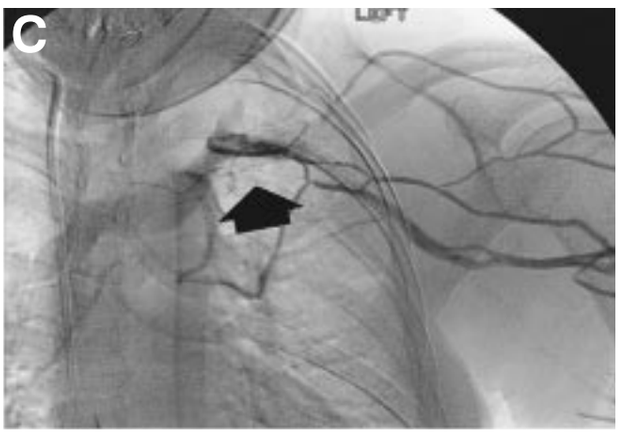

Figure 33.22 Large metastatic and recurrent breast carcinoma involving the entire axillary space. (**A**) Coronal MRI shows the entire axillary space is filled with tumor (solid arrow). The tumor extends from the chest wall to the lateral border of the space, and extends superiorly from the clavicle to below the inferior margin of the pectoralis major muscle. (**B**) Axial T2- weighted view demonstrates tumor involvement of the anterior and posterior walls of the axilla as well as the chest wall. This patient required a palliative forequarter amputation. (**C**) Axillary venograph demonstrating complete occlusion of the mid-axillary vein. Axillary vein occlusion (arrow) is pathognnomic of brachial plexus involvement by tumor and almost always indicates unresectability.

pectoralis fascia. These are the pectoralis minor muscle (arises from the chest wall and attaches to the coracoid) and the conjoined tendon (arises from the coracobrachialis and short head of the biceps from the medial aspect of the humerus). These two muscles must be identified in the clavicular–pectoralis fascia during the surgery. This identification is the key to accurate identification and dissection of all structures thar are located more deeply within the axillary fat.

Infraclavicular Brachial Plexus

The infraclavicular portion of the brachial plexus is the most significant anatomic component involved in surgery in the axillary region; therefore it must be thoroughly evaluated and its anatomy must be completely understood. The axillary artery and vein are contained within a single sheath and surrounded by the cords of the infraclavicular plexus. The lateral, posterior, and medial cords of the plexus are found at the level of the pectoralis minor muscle. At the lower border of the pectoralis minor muscle these cords give rise to the five major nerves of the extremity: median, ulnar, radial, musculocutaneous, and axillary nerves.

The lateral cord gives rise to the musculocutaneous nerve, which travels along the medial aspect of the conjoined tendon and enters into the muscle belly of the

Malawer Chapter 33 22/02/2001 09:17 Page 543

Figure 33.23 CT scan shows a large metastatic melanoma filling the axillary space. The tumor (solid arrows) involves te subscapularis muscle posteriorly and the pectoralis major muscle anteriorly. The axillary vessels are seen displaced (open arrow). CT and MRI are extremelt useful in determining the bony and soft-tissue involvement and extension, respectively, into the axillary space.

coracobrachialis and then into the short head of the biceps. This nerve is the first to be identified during the exploration. It is located in the superficial axillary fat inferior to the coracoid process. The posterior cord gives rise to the axillary nerve, which travels deep in the space and passes inferior to the glenohumeral joint and subscapularis muscle. The axillary nerve innervates the deltoid muscle. The main portion of the posterior cord becomes the radial nerve, which travels posterior to the sheath and exits the axillary space along with the axillary sheath. The medial cord gives rise to the median nerve, which is found on the lateral aspect of the sheath and exits the inferior aspect of the axillary space along the sheath. The ulnar nerve arises from the median cord and travels along the most medial aspect of the sheath and exits distally along with the sheath. Because of its medial position along the sheath, the ulnar nerve is the most common nerve to be involved by tumors arising inferior to the brachial plexus. This nerve often displays the first symptoms of brachial plexus involvement, which may be either weakness or neuropathic complaints.

Axillary Artery and Brachial Artery

The axillary artery is a continuation of the subclavian artery as it passes below the clavicle and the first rib. As it exits the axillary space just distal to the take-off of the circumflex vessels it is termed the "brachial" artery. This transition occurs at the level of the inferior pectoralis major and teres major muscles, anteriorly. From an anatomic perspective the axillary artery is considered to consist of three segments. The first segment is the length between the clavicle and pectoralis minor. The second is the area under the pectoralis minor, and the third is the segment between the inferior lateral pectoralis minor border to the point of exit below the teres major muscle. Tumor involvement may occur secondary to lymph-node metastases in any of these three locations. The most common sites for axillary sarcomas are the second and third segments. Metastatic carcinomas involving the axillary space can involve any of these areas; however, they most often present as large, matted tumor masses between areas two and three.

Staging Studies

Three-dimensional imaging of the axillary space is important for accurate anatomical tumor localization and surgical planning. (Figures 33.21–33.23) Computerized tomography (CT), magnetic resonance imaging (MRI), angiography, and three-phase bone scans are used in the same manner as they are in other anatomic sites. In addition, we have found that venography of the axillary and brachial veins is essential to the evaluation of tumors of the axilla and brachial plexus.

Computerized Tomography

CT is most useful in evaluating the bony walls of the axilla, specifically the humerus, glenohumeral joint, and scapula (Figure 33.23). Soft-tissue tumors are well defined by CT scans. CT scans with IV contrast aid in the definition of the axillary vessels.

Magnetic Resonance Imaging

MRI is extremely useful in determining the extent of a soft-tissue mass in the axillary space and the involvement of the underlying serratus anterior and/or the anterior and posterior walls of the axillary space (pectoralis major, subscapularis, latissimus dorsi, and teres major muscles) (Figure 33.21).

Angiography

Angiography should be part of the evaluation of all tumors of the axillary space (Figure 33.21C). It will demonstrate any vascular displacement (very often inferior or anterior) and vascular anomalies of the axillary vessels. In addition, it can provide evidence of induction chemotherapy response to (i.e. a decrease) in tumor vascularity.

Venography

Venography is one of the most accurate means of determining of brachial plexus and axillary sheath involvement or infiltration by tumor (see Figure 33.22C). The arterial wall is thick and rarely shows signs of occlusion, whereas the axillary vein is a thin-walled structure that is easily compressed and infiltrated by tumor. Therefore, occlusion is almost synonymous with vascular sheath and brachial plexus involvement. Venography is routinely performed to evaluate the axillary vein. We have found that a positive venogram showing occlusion of the vein, in combination with neurological pain and weakness, is almost always pathognomonic of axillary sheath and brachial plexus involvement by tumor. The triad of axillary venous occlusion, distal motor weakness, and neuropathic pain is a very reliable predictor of tumor infiltration of the brachial plexus sheath.

Biopsy

Biopsy of axillary tumors should be performed utilizing a needle or fine-needle aspiration (FNA) technique. If a metastatic lesion is likely, FNA is the most appropriate means to identify carcinoma cells. If one suspects a sarcoma a core needle biopsy should be performed. The biopsy should be performed through the base of the axillary space, and not through the pectoralis major muscle or near the vascular sheath. This can easily be performed under CT guidance. Deep-seated lesions near the chest wall can also be approached in this manner. Anterior lesions, on occasion, can be approached through the lower portion of the pectoralis major muscle. The biopsy site must be removed in its entirety during resection of the tumor.

Surgical Guidelines

1. *Incision*. Anterior utilitarian incision with axillary extension is utilized. This incision extends along the deltopectoral interval and entails preservation of the cephalic vein. The incision then curves inferiorly and distally over the base of the axilla.
2. *Detachment of the pectoralis major muscle*. The pectoralis major is detached from its insertion on the humerus and is reflected towards the chest wall while maintaining its vascular pedicles. This permits exposure of the entire axillary space and fascial sheaths.
3. *Development of the anterior axillary fascial plane (claviculopectoralis fascia)*. This is a thick, well-defined layer of fascia that contains the entire axillary space and structures. This plane must be developed prior to any further dissection.
4. *Release of the pectoralis minor and conjoined tendon*. The pectoralis minor and conjoined tendon form the anterior muscle layer within the axillary space. Release of these muscles is key to exposure of the vascular sheath, the brachial plexus, and the numerous vascular branches feeding any large tumors.
5. *Identification of the musculocutaneous nerve and the axillary nerve*. The musculocutaneous nerve comes around the lower border of the coracoid under the pectoralis minor muscle. The axillary nerve comes off deeper from the posterior cord and travels toward the shoulder joint. Both must be identified at this stage.
6. *Mobilization of the axillary sheath and brachial plexus*. Proximal and distal control of the vascular sheath is obtained prior to tumor dissection. Once the deep fascia is opened, and the pectoralis minor muscle is released, the sheath is found very easily by palpation of the axillary fat. Vessel loops are placed around the entire sheath; there is no need to dissect the individual components.
7. *Resection of tumor*. All of the feeding branches entering into the mass are serially ligated and transected. Axillary fat is left around the tumor mass as the only true margin.
8. *Closure*. The pectoralis minor and conjoined tendon are reattached to the coracoid process.
9. *Insertion of catheter.* An epineural catheter is placed in the axillary sheath for postoperative pain relief.
10. *Closure of the empty space*. Following resection, there is often a large empty space that is prone to collect fluid. This may lead to wound complications and dehiscence. To close this space the latissimus dorsi may be released from its insertion onto the humerus, inserted into the defect, and sutured to the subscapularis muscle.
11. *Postoperative management.* The arm is suspended and kept adducted at the side of the body to close off this space. Multiple drains are utilized for 4–7 days.

Malawer Chapter 33 22/02/2001 09:17 Page 545

Surgical Technique

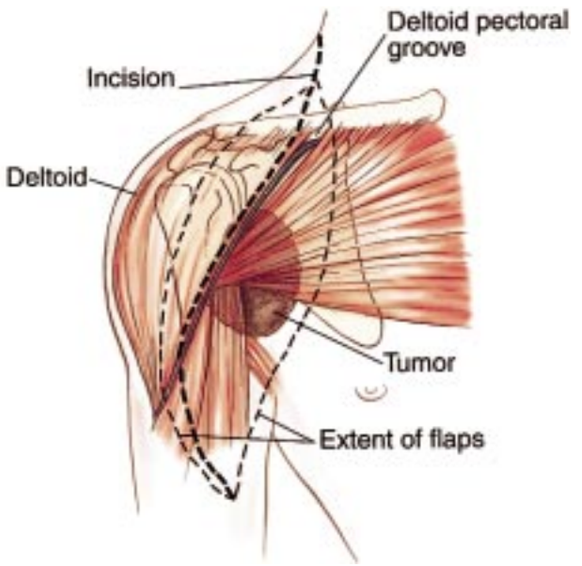

Figure 33.24 Incision. The tumor is shown under the pectoralis major muscle within the axillary space. The patient is placed in a supine semilateral position. The arm, shoulder girdle, and chest are also prepared and draped. Full mobilization of the ipsilateral extremity is essential. A deltopectoral incision is used; it starts over the junction of the inner and middle thirds of the clavicle, continues along the deltopectoral groove, and curves distally over the anterior axillary fold (inferior border of the pectoralis major muscle). The superficial fascia is opened, the cephalic vein is ligated or preserved, and medial and lateral fasciocutaneous flaps are raised.

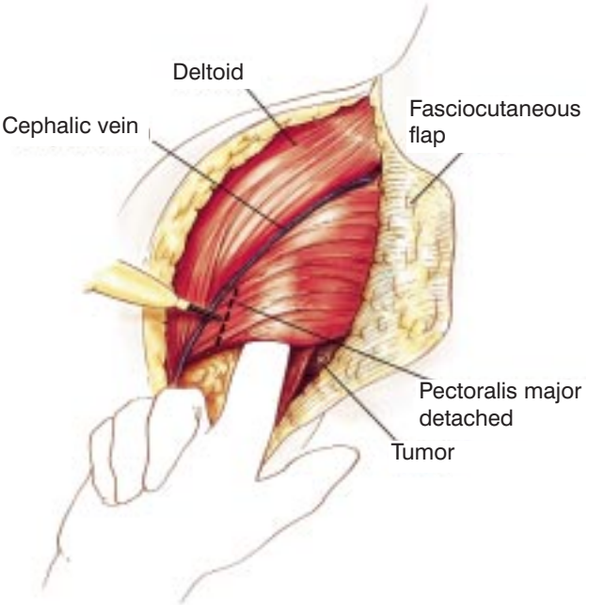

Figure 33.25 Detachment of the pectoralis major. The pectoralis major muscle is detached from its insertion to the proximal humerus, leaving at least 1 cm of the tendon for reattachment. Care must be taken to protect the axillary vessels. Large axillary tumors may displace the axillary sheath anteriorly and adjacent to the pectoralis major muscle.

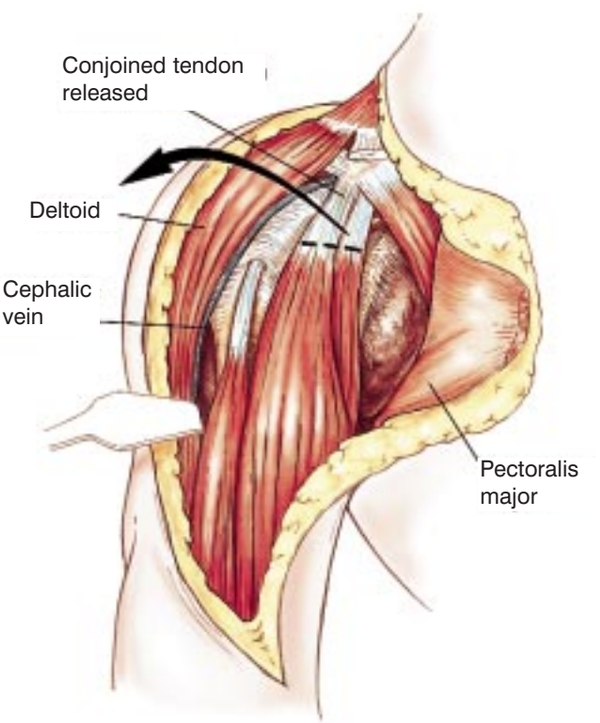

Figure 33.26 *(right)* Muscle division. The short head of the biceps and coracobrachialis (conjoined tendon) and pectoralis minor muscles are divided at their insertion on the coracoid process. Reflection should be performed with caution to prevent traction injury to the musculocutaneous nerve.

Malawer Chapter 33 22/02/2001 09:17 Page 546

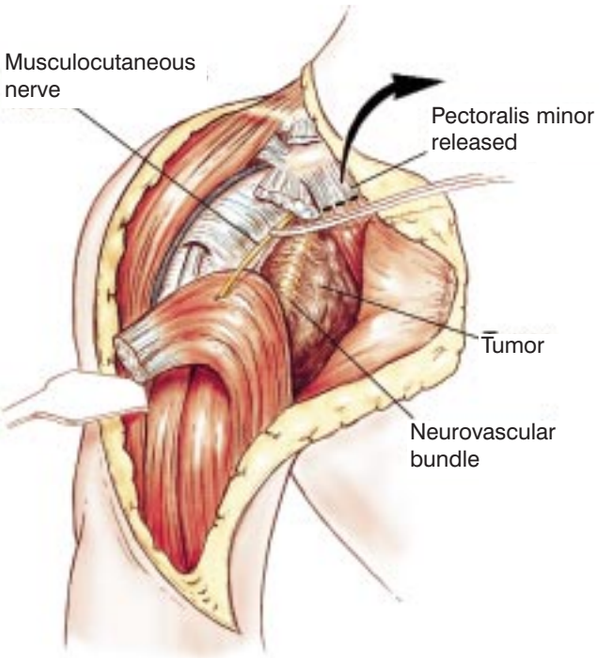

Figure 33.27 Detachment of the pectoralis minor and conjoined tendon. The axillary cavity is exposed after detachment and reflection of two muscle layers. The pectoralis minor muscle is reflected medially, and the conjoined tendon (coracobrachialis and biceps muscles) is reflected caudally. All edges of reflected muscles are tagged with a suture for later identification and use in reconstruction.

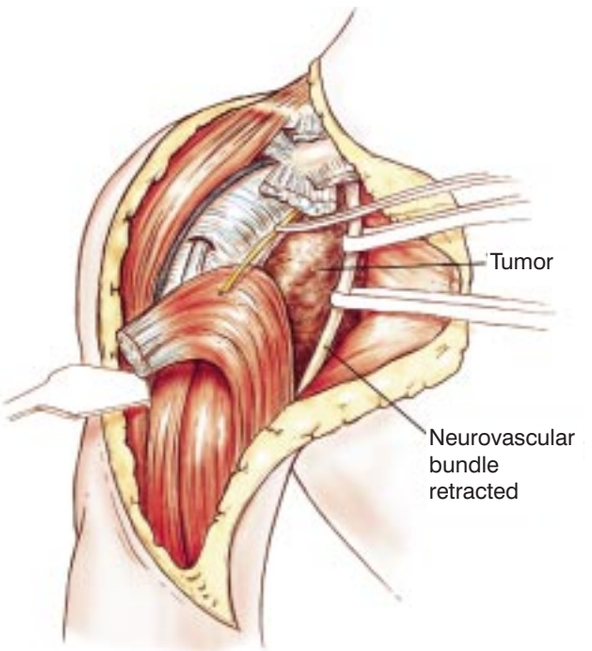

Figure 33.28 The deep axillary fascia, neurovascular bundle, and content of the axillary cavity are now fully exposed. The anatomic relation of the tumor to the neurovascular bundle can be determined and the decision regarding tumor resectability made. At this anatomic site the artery, vein, and brachial plexus are in close relation, and tumor extension to the neurovascular bundle usually affects all its components and negates resection. Benign tumors and soft-tissue sarcomas usually push the adjacent neurovascular bundle; only at a later stage do soft-tissue sarcomas actually break into it. Metastatic carcinomas directly invade the surrounding tissues, irrespective of compartmental borders. For these reasons, resection of large metastases with preservation of the neurovascular bundle is occasionally not feasible.

Malawer Chapter 33 22/02/2001 09:17 Page 547

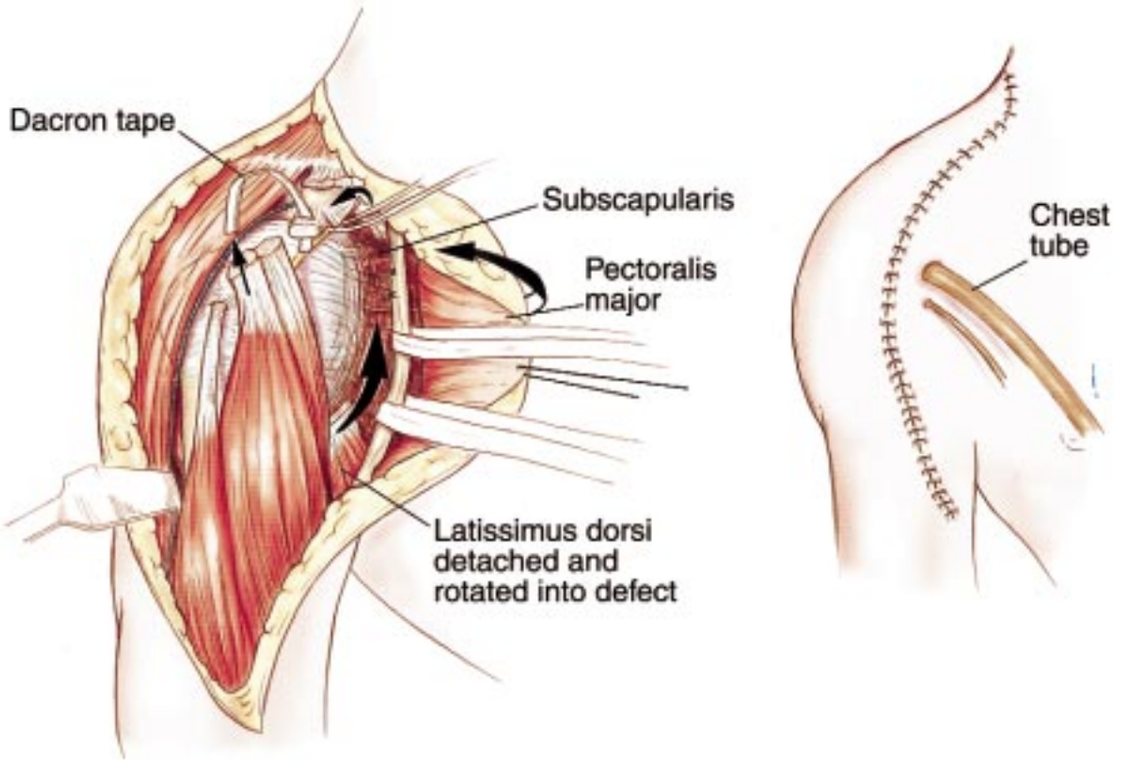

Figure 33.29 Reattachment of the conjoined tendon and pectoralis minor muscles and closure. Following resection the pectoralis minor and conjoined tendons are reattached to the coracoid process with a nonabsorbable suture, and the pectoralis major is reattached to its insertion site on the proximal humerus in the same manner. The wound is closed over suction drains. The upper extremity is placed in an arm sling. Continuous suction is required for 4–7 days; perioperative intravenous antibiotics are continued until the drainage tubes are removed. Postoperative mobilization with gradual range of motion of the shoulder joint is then introduced.

Figure 33.30 (*see following page*) Anterior axillary mass arising from the scapula. (**A**) Clinical photographs shows a large axillary tumor (T) underlying the pectoralis major muscle and arising from the anterior surface of the scapula and suprascapularis muscle. This tumor was easily palpable immediately below the pectoralis major muscle. Surgical exposure (**B–D**): a transpectoralis axillary incision was utilized to expose the axillary space and brachial plexus and vessels prior to resection of the scapula from the posterior approach. The combination of the anterior and posterior approaches is termed the "utilitarian" surgical approach for the shoulder girdle. (**B**) Intraoperative photograph shows the pectoralis major muscle (solid arrow) that makes up the anterior wall of the axilla. This muscle is deteched through the deltopectoral interval from the insertion onto the humerus and is reflected towards the chest wall, exposing the axillary contents and the deep layer of muscle (small arrow), the coracobrachialis, and the short head of the biceps inserting onto the coracoid. The entire axillary space is easily visualized through this approach. Axillary fat, covered the clavicular–pectoralis fascia, makes up this entire space (small arrow). (**D**) Surgical dissection of the infraclavicular portion of the brachial plexus (Penrose drain and vessel loop) demonstrating a large anterior mass (T, solid arrow) that displaces the sheath anteriorly. Note the intimate apposition of the vascular sheath to the tumor (small arrows). This approach is an extremely safe and reliable method of mobilizing the brachial plexus in patients with large tumors of the axillary space.

Malawer Chapter 33 22/02/2001 09:17 Page 548

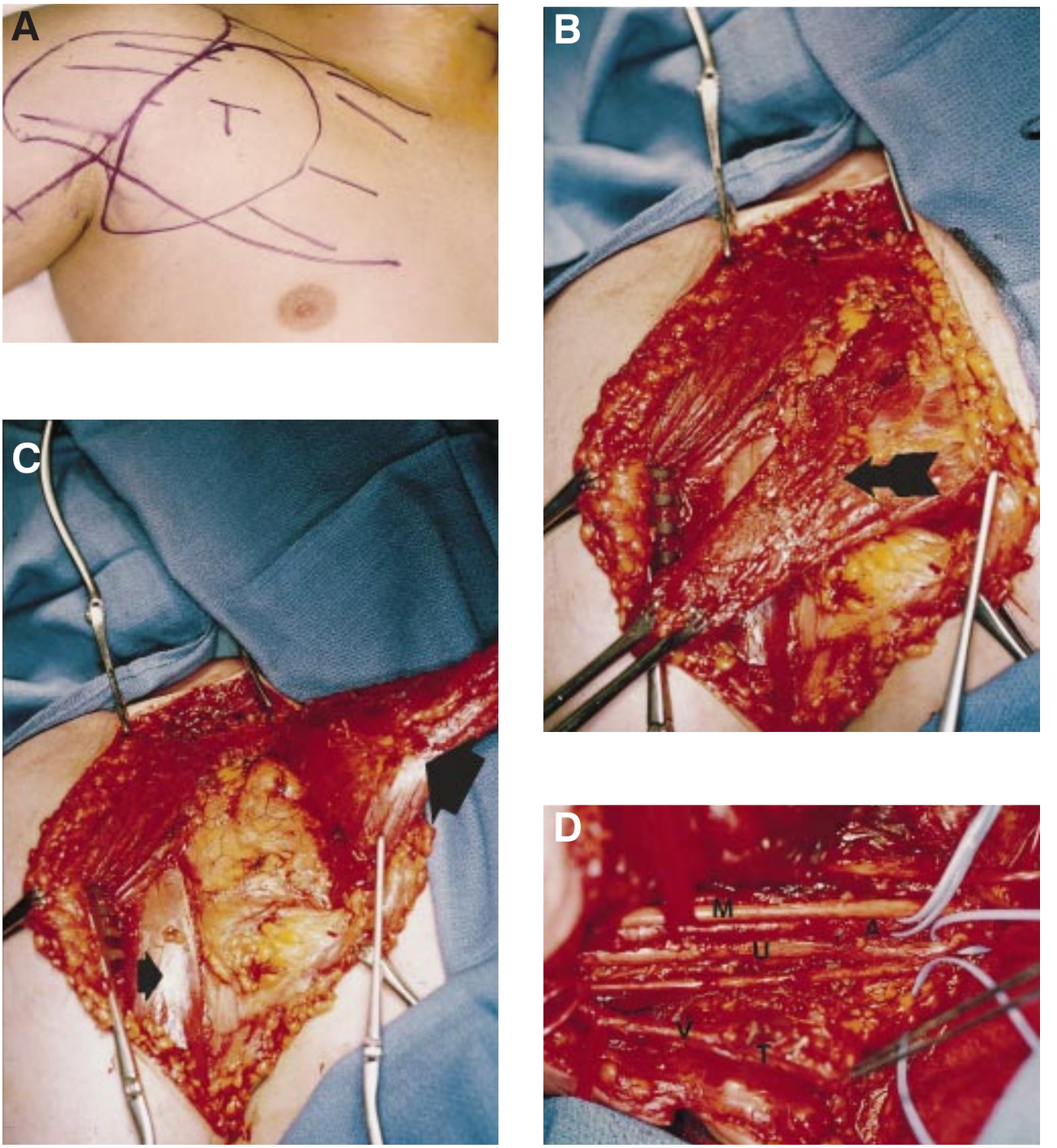

Figure 33.30 A–D

Malawer Chapter 33 22/02/2001 09:17 Page 549

Figure 33.31 Infraclavicular plexus dissection for hemangioendothelioma of the axillary vein presenting with ulnar nerve symptoms. This is an intraoperative photograph of the infraclavicular portion of the brachial plexus in which the sheath had been completely opened by all five terminal nerves identified. The terminal five nerves of the brachial plexus are: musculocutaneous, axillary, radial, ulnar, and median. The transpectoralis approach was utilized for this resection. This patient has been initially treated by inadequate resection through a small axillary incision that necessitated this re-exploration and resection. The axillary vein has been retracted and the axillary artery is identified. The tumor (T) arose from the wall of the axillary vein and was pressing on the medial cord and ulnar nerve (arrows), accounting for the ulnar nerve symptoms.

Figure 33.32 Intraoperative photograph of the transpectoralis approach was utilized for an intra-articular resection of a proximal humerus osteasarcoma. The pectoralis major muscle had been detached from the humerus and reflected toward the chest wall. The deeper layer, consisting of the conjoined tendon and pectoralis minor muscles, was detached from the coracoid and reflected medially. This exposes the infraclavicular plexus (large solid arrow). The musculocutaneous (M) and axillary nerves (A, superior vessel loop and small arrows) were initially dissected and preserved. Intra-articular resections require preservation of the axillary nerve (A). This approach is extremely useful for large tumors of the proximal humerus with an extraosseous component.

References

1. Malawer MM, Link M, Donaldson S. Sarcomas of bone. In: Devita VT, Hellman S, Rosenberg SA, editors. Cancer: Principles and Practice of Oncology, 3rd edn. Philadelphia: JB Lippincott; 1989.
2. Malawer MM, Sugarbaker PH, Lambert MH *et al*. The Tikhoff–Linberg procedure and its modifications. In: Sugarbaker PH, editor. Atlas of Sarcoma Surgery. Philadelphia: JB Lippincott; 1984.