

35

Anesthesia and Perioperative Pain Management for Limb-sparing Surgery

Avi A. Weinbroum, Nissim Marouani, Eric Lang, David Niv and Valery Rudick

OVERVIEW

????

THE ANESTHESIOLOGIST AND THE ONCOLOGICAL PATIENT

Anesthesiologists become involved in the care of patients with malignant disease whenever such patients require pain relief. This involvement may occur at any stage in the disease process. During the perioperative phase, for example, it is the anesthesiologist who develops the patient's individualized pain-control protocol. For patients who require surgery the anesthesiologist is a pivotal member of the team who determines the extent and timing of surgery. Safe intraoperative care of the oncological patient poses a number of challenges to the anesthesiologist. First, tumors are accompanied by widespread pathophysiological changes caused by the physical and mental stress associated with a sudden need for major surgery. In addition, a variety of side-effects may accompany synergistic treatment protocols (i.e. radiotherapy and chemotherapy) that are used to bring about optimal regression of the tumor prior to surgery. Aggressive surgical applications may often require long-term anesthesia, prolonged postoperative analgesia, or even admission to an intensive-care unit.¹

GENERAL CONSIDERATIONS

Because of the variety of disorders that accompany cancer in general, and sarcomas in particular, assessment of baseline and psychological condition of the patient, and optimizing his or her status prior to surgery, are a fundamental priority of the anesthesiologist. Information can be obtained from the patient and the family, the medical records, the attending physician, or a physician-consultant. These patients have invariably already undergone some investigational workup and conservative treatment by the time they are first seen by the anesthesiologist. Many patients with sarcoma are young and rarely suffer from age-related illnesses such as ischemic cardiac disease or hypertension.

Respiratory or behavioral disorders, by contrast, are more common and may exist in association with previous treatment (chemotherapy, immunosuppressive therapy, or radiotherapy), metastasis, or previous surgery. In these cases it is important to assess any existing limitations as would be appropriate for any chronic disease, using the patient's ASA grade.

PERIOPERATIVE CONSIDERATIONS

Patient Evaluation and Preparation

It is vital to evaluate the patient's initial condition in order to ensure the best outcome (Table 35.1). The diagnosis of a malignancy and the necessity for surgery

Table 35.1 Preoperative collective concerns and complications in the cancer patient

Weight loss, anorexia
Fever, chills, sweats
Dehydration
Weakness, fatigue
Coagulopathy
Anemia, polycythemia
Thrombocytopenia, dysfunctional platelets
Adrenal insufficiency
Ectopic hormone production
With chemotherapy/radiation treatment:
Autonomic neuropathy
Gastroparesis
Tachycardia, dysrhythmias
Orthostatic hypotension
Electrolyte imbalance
Hyperuricemia
Pericardial effusion and tamponade
Cardiomyopathy
Cardiac failure
Neuromuscular abnormalities
Ureteral obstructions
Nephrotic syndrome
Tumor lysis syndrome
Superior vena cava syndrome
Spinal cord compression syndrome
Brain metastases
Mental status changes

may understandably induce a heightened level of anxiety, nervousness, or feelings of denial and rage in an otherwise healthy patient, especially a teenager and his or her family. Patients may ask numerous questions and require intensive psychological support. Some may need anxiolytic drugs. For patients who appear apathetic or depressed, and wish no verbal contact or explanation of what to anticipate, anesthetic drugs may not be required. Prior chemotherapy or radiation, combined with symptoms of organ dysfunction, put an additional burden on the patient. Finally, the patient may also be threatened by the idea of anesthesia. The anesthesiologist should confer with the patient for as long as required to reduce his or her anxiety, and should offer candid explanations of the planned anesthesia, perioperative care, and the selected option of postoperative pain control. Appropriate preoperative medication is also useful for most patients.

Unless brain metastases are present neurological symptoms are rare with sarcoma. These symptoms include headache, nausea, dysphagia, abnormal sensations (e.g. dysesthesia or paresthesia), visual disturbances, loss of sensation, and motor dysfunction.

Results of the neurologic examination should be available to the anesthesiologist, as should results of the peripheral electromyography and computerized axial tomography (CAT) of the brain. The anesthesiologist should meticulously evaluate the mobility and function of the neck, mouth, throat, and muscles of the upper extremities.

The cardiovascular system may be involved in tumors or metastases, or obstruction of the inferior or superior vena cava (vena cava compression syndrome). The patient's history may contain signs and symptoms of congestive heart failure, including dyspnea or pulmonary edema. Complaints of facial and arm redness or puffiness, or changes in skin color, may indicate superior vena cava syndrome. Objective physical findings might include caput medusae and venous engorgement, edema of head and neck, or a third heart sound (with or without rales over the pulmonary fields). Chest X-rays and echocardiography will provide further information in such cases. A preoperative cardiac stress test and/or angiography should be considered in patients with chest angina. The respiratory system may be involved as a result of a hematogenously disseminated tumor embolus that causes dyspnea, or of chemotherapy or radiotherapy applied to the thorax. Chest films, arterial blood gases, and/or isotope imaging of the pulmonary vascular bed help differentiate among these conditions.

The presence of a neurosarcoma, chondrosarcoma, or osteosarcoma in the abdominal cavity (either intra- or retroperitoneal) may compromise intra-abdominal organ function. Gastroparesis and bowel obstruction may explain complaints of early satiety, pain, or frequent vomiting. Distension of the abdomen may not be noted on physical examination. Plain X-ray films or CAT of the abdomen may then be indicated. Sarcoma of the ampoule of Vater can present with liver dysfunction, as is the case of hepatic metastases. In both cases, liver function tests are warranted. Compression of the ureters by a retroperitoneal tumor is not infrequent and may lead to renal insufficiency and uremia. Kidney function tests and ultrasonic visualization of the renal excretory component may be indicated preoperatively.

Preoperative insertion of an intraureteral catheter to safeguard lumen patency may be necessary in such cases, especially in pediatric patients who require preoperative sedation or anesthesia. The use of contrast media should be discouraged in patients with poor renal function.

Hematological and biochemical profiles are important when evaluating the need for correction of preoperative anemia or coagulopathy. Hyper- or hypo-coagulability states may not be noticeable unless prothrombin time or activated partial thromboplastin

time is measured. The latter can be associated with a moderate degree of anemia, which is a consequence of intestinal bleeding.

Patients suffering from bone loss due to osteosarcoma may show clinical or subclinical signs of hypocalcemia. This condition may be accentuated in the presence of malnutrition or hepatic dysfunction.² Blood levels of both albumin and calcium should be normalized to avoid cardiovascular manifestations of hypocalcemia and pharmacokinetic disturbances of intraoperative anesthetics such as muscle relaxants.²

Patients with cancer experience various types of pain (i.e. acute, chronic, intermittent, continuous). The Task Force on Pain Management of the American Society of Anesthesiologists concluded that half of the cancer patients suffer from chronic pain.³ With more advanced and terminal disease this figure increases to two-thirds. The effect of pain on the individual is variable. Patients with sarcomas usually present with some degree of pain and are already under some sort of analgesic regimen. Moreover, one type of pain may be superimposed on another. Cancer-related pain management commonly starts with non-narcotic agents such as nonsteroidal anti-inflammatory drugs. If the pain does not subside, the next drugs of choice are usually opioids.

The Pediatric Oncology Patient

A child is a difficult patient whose responses to the many procedures associated with cancer therapy are unpredictable. Children may feel physically and psychologically handicapped in comparison with their peers. Frequent courses of chemotherapy and radiotherapy, blood transfusions, and other sources of discomfort from procedures are difficult for them to accept.⁴ It is essential that the anesthesiologist, together with the rest of the surgical team, talk to the pediatric patient using words and concepts that he or she can understand. Prevention of unnecessary distress or suffering, such as prolonged queuing or long fasting hours, is essential.

Young children undergoing an investigational workup (e.g. roentgen imaging) or radiotherapy to reduce a large sarcoma may require sedation or anesthesia in order to keep them motionless during the procedure. An inhalation technique allows for rapid awakening and is preferred to parenteral sedatives such as benzodiazepines. Sevoflurane is ideal for this purpose because of its low solubility and lack of pungency.⁵

The Patient with Previous Antitumoral Therapy

The first line of therapy for various tumors at different stages is chemotherapy that interferes with cell

proliferation. The characteristics of several agents that are most frequently used to treat the patient with sarcoma are listed in Table 35.2. The toxicity exerted by these agents and their relevance to the perioperative anesthesia management are directly related to the agent used, the cumulative dose, the damage inflicted on specific organs (including damage caused in the past) and, possibly, cotreatment with synergistic antitumoral agents. The bone marrow, gastrointestinal tract, and blood-circulating elements, all of which are

sometimes associated with ulceration and bleeding in the skin and mucosal layer, are most severely affected by the toxic effects of these agents. Acute or residual pulmonary and cardiac toxicity is also a concern.

Radiotherapy is a second choice of presurgical treatment. The use of powerful, high-precision radiation generators has minimized unnecessary body exposure and the incidence of side-effects such as nausea, vomiting, general sickness, abdominal cramps, and lung tissue changes (Table 35.3). The use of antiemetics

Table 35.2 Preoperative toxicity of selected chemotherapeutic agents

Therapy	Signs and symptoms
Alkylating agents	Nausea, emesis, bone marrow depression, agranulocytosis, anemia, thrombocytopenia, hemorrhagic cystitis, alopecia, uric acid nephropathy
Busulfan, chlorambucil	Pulmonary toxicity
Busulfan, cytoxan	Cardiac toxicity
<i>Anesthesia preoperative concern:</i> Cytoxan may cause a prolonged response to succinylcholine due to cholinesterase inhibition	
Antimetabolites	Nausea, emesis, gastrointestinal toxicity with bleeding, diarrhea, dehydration, acute and chronic hepatitis
5-Fluorouracil	Bone marrow depression, megaloblastic anemia, acute cerebellar syndrome, gastrointestinal and hepatic toxicity
Methotrexate	Bone marrow depression, interstitial pulmonary infiltrates, ulcerative stomatitis, renal tubular necrosis, hepatic dysfunction
<i>Anesthesia preoperative concern:</i> 6-Mercaptopurine can cause nondepolarizing muscle relaxant neuromuscular blockade	
Antineoplastic alkaloids	Neurotoxicity with peripheral paresthesia, muscle wasting, loss of deep tendon reflexes
Vinblastine	Bone marrow depression, myelotoxicity, antidiuretic hormone secretion
Vincristine	Ventricular tachycardia, hypo- or hypertension, peripheral neuropathies, bronchospasm
Paclitaxel	Arrhythmias, atrial ventricular block, bone marrow suppression
<i>Anesthesia preoperative concern:</i> Vincristine may elevate potassium secondary to muscle wasting. Use caution with succinylcholine. Laryngeal muscle paralysis can occur	
Anthracycline antibiotics	Bone marrow depression, myelotoxicity, cardiomyopathy with congestive heart failure, decreased left ventricular ejection fraction, biventricular failure
Bleomycin	10% pulmonary toxicity, interstitial fibrosis, renal parenchymal failure
<i>Anesthesia preoperative concern:</i> Bleomycin patients keep at $FiO_2 \leq 28\%$ to avoid progressive pulmonary fibrosis and edema. Maintain fluid restriction, monitoring, and colloid administration	
Miscellaneous agents	
Cisplatin	Renal damage with decreased clearance, neuropathy, including stocking/glove paresthesia, areflexia, ocular toxicity and loss of hearing, bronchospasm, cardiac arrhythmias

Table 35.3 Preoperative effects and concerns of radiation therapy

<i>Organ</i>	<i>Acute (up to 4 weeks)</i>	<i>Intermediate (1–3 months)</i>	<i>Late (several months to years)</i>
Skin	Erythema, rash, hair loss		
Gastrointestinal	Malnutrition, anorexia, nausea, emesis, esophagitis, dehydration, gastroenteritis, stomatitis	Bowel adhesions and obstruction, enteric fistula	
Cardiac			Pericarditis, pericardial effusion, fibrosis
Pulmonary			Pleural effusion, fibrosis, pneumonitis, esophageal–tracheal fistula
Hematologic	Bone marrow depression		
Additional anesthesia concerns	Electrolyte abnormalities, fluid volume status	Fluid volume status, ascites with subsequent respiratory compromise	

(e.g. metoclopramine, droperidol, or ondansetron) and a short course of corticosteroids (e.g. dexamethasone or a 5-HT₃ antagonist), plus a dopaminergic antagonist, may alleviate these symptoms.⁶ Since bone marrow suppression may occur after large-scale bone irradiation, a full hematologic profile should be performed prior to surgery.

PREOPERATIVE VISIT AND DRUG ADMINISTRATION

It is important that the patient meet the anesthesiologist prior to surgery. A good relationship may comfort the patient so that mild sedation may suffice prior to commencement of anesthesia. It is good practice not to administer drugs intramuscularly. Oral or rectal administration, or the use of a pre-existing intravenous line, is psychologically and physically less traumatic. These drugs can be administered shortly before the patient is brought into the operating room. Metoclopramide, sodium citrate, and other drugs are highly recommended in patients with gastroparesis or decreased intestinal motility. Ondansetron is the most effective antiemetic for the management of patients receiving chemotherapy or radiotherapy;⁷ it can be administered enterally or parenterally.

Electrolyte and fluids should be administered before surgery by the attending physician and revised, if necessary, by the anesthesiologist. Volume replacement is frequently needed in the oncological patient because

of the decreased drinking, repeated bowel preparation prior to surgery, or the need for relative hyperhydration to ameliorate renal dysfunction. Volume replacement should be performed cautiously in patients with a history of congestive heart failure or ischemic heart disease.

ANESTHESIA

The factors that may have the greatest negative influence on the patient outcome are anemia and thrombocytopenia, immune suppression, and renal or cardiac dysfunction. These must be evaluated pre- and postoperatively. Blood must be available, and antibiotic treatment should be initiated in advance unless a sample from a suspected infected area is to be retrieved for culture and antibiogram. Major surgical procedures such as hemipelvectomy or resection of a retroperitoneal sarcoma, require large-bore intravenous lines as well as arterial lines. Central venous measurement is helpful in assessing changes in circulating blood volume in procedures that cause severe bleeding, and in caring for patients who require good hydration to optimize renal function but also present symptoms of myocardial insufficiency. Patients who are hemodynamically fragile or suffer from cardiac or pulmonary disease may benefit from the insertion of a balloon-tipped intrapulmonary (Swan–Ganz) catheter, which allows judicious administration of volume therapy instead of vasoactive drugs.

GENERAL ANESTHESIA

Special Considerations

Besides standard monitoring (i.e. electrocardiography, noninvasive blood pressure, and pulse oximetry), additional monitoring may be required. The risk of aspiration exists in patients with a large abdominal mass, gastroparesis, or increased intracranial pressure, as well as in those who suffer from postchemotherapy or radiation sickness. One way to reduce this risk and provide good anesthesia is to apply an epidural or spinal block. If general anesthesia is indicated, it should be carried out cautiously. The airway should be protected with the Selick maneuver or by awake intubation, preferably after the stomach has been emptied. Caution should be paid in patients with cardiac dysfunction (post-chemotactic, radiation, or postischemic) or myocardial involvement to a myxoma. Patients with hypovolemia (caval compression syndrome) may be hemodynamically unstable. Profound hypovolemia is a contraindication to centroneural regional anesthesia.

Maintenance of Anesthesia

There are no contraindications to the use of any anesthetic drug, either inhalation or intravenous, in patients with sarcoma. Patients with altered organ function may exhibit clinically significant abnormal responses to some drugs, especially those that depend on hepatic metabolism or renal excretion. Large tumors may bleed and require replacement of 2–4 units of blood. Hemodilution can decrease the rate of intraoperative blood loss and the necessity for controversial allogenic blood transfusion;⁸ however, it could lead to hemodynamic instability, especially in patients with preoperative anemia or autonomic system deficiency. During prolonged major surgery (e.g. hemipelvectomy), the effects of prolonged intravenous or inhalation anesthesia may become clinically apparent. An intravenous drug infusion will result in a lower cumulative drug dose than repeated boluses.⁹

Various drugs can be used for induction and maintenance of anesthesia in the oncology patient. Their common characteristics are the ability to induce complete amnesia and a rapid onset of deep sedation or hypnosis and the ability to be synergistic with other intravenous or inhalation agents. Propofol has a rapid onset and recovery and can be used by infusion. It also exerts some antiemetic effect and has fewer side-effects than other general anesthetics. However, caution should be paid when propofol is administered to patients who are hypovolemic, hemodynamically unstable, or who suffer from hepatic dysfunction.¹⁰ Midazolam, a water-soluble benzodiazepine, is frequently used

during induction and maintenance of anesthesia for short-lasting procedures, interventions that require monitored care anesthesia, or chemotherapy sessions in children. The subsequent central respiratory depression is not as profound as that following opioids or hypnotics, although recovery is somewhat prolonged.¹¹

During the past 10 years isoflurane has almost completely replaced halothane. Isoflurane is frequently used for maintenance of anesthesia in both adults and children. Sevoflurane is a novel inhalation agent that produces virtually no upper-airway irritation, even when given a high minimal alveolar concentration (MAC).⁵ It is an excellent agent for pure inhalation induction in children, as well as for maintenance in patients of all ages. Nausea and vomiting are less frequent in patients who have received sevoflurane than in those who receive desflurane or isoflurane.¹² Because it is quick and smooth both during induction and recovery, sevoflurane is a good choice for short chemotherapy or radiotherapy sessions in children, especially when intravenous lines are unavailable prior to the intervention. Nevertheless, agitation can ensue following administration of this agent, especially in the pediatric population, and particular attention must be paid to patients who have received sevoflurane. During the immediate postanesthesia period, low-dose midazolam can control the agitation.¹¹ Desflurane, an inhalation agent with a rapid onset, is especially useful for ambulatory surgery. It is not recommended for induction in the pediatric population because of its association with a high incidence of coughing and laryngospasm.¹³

Muscle relaxants are used in combination with other anesthetic drugs. The new short-acting drugs have fewer side-effects and provide better manageability and the possibility of prompt cessation of general anesthesia. These include atracurium, vecuronium, mivacurium, and rocuronium.

Opioids, including fentanyl, sufentanyl, alfentanyl, and remifentanyl, are frequently used during anesthesia. Sufentanyl is one of the most widely utilized drugs because of its rapid onset time and short elimination half-life.¹⁴ It is seven to ten times more potent than fentanyl. Because it does not accumulate within the body, sufentanyl is the drug of choice in prolonged surgical procedures. Remifentanyl is a novel, extremely short-acting opioid that is metabolized by pseudocholinesterase. Its half-life is approximately 10 minutes. Alfentanyl is a short-acting opioid with a rapid onset. Its duration of action is two to three times shorter than that of fentanyl; however, this property also limits the drug's postoperative analgesia efficacy. Pharmacokinetically, alfentanyl is one of the few opioids indicated for day surgery.¹⁴

Oncological patients are more prone than other patients to develop pulmonary embolism and regional thrombosis in the postoperative period. This is because of circulating procoagulation factors, such as tumoral debris and their overturned fragments, or prolonged surgery.¹⁵ Prophylactic anticoagulation with low-dose or low-molecular-weight heparin, may prevent these complications.¹⁶ The risk-to-benefit ratio of performing a neural block in a partially anticoagulated patient is debatable. Continuous infusion of local anesthetics and/or opioids in a preinserted epidural catheter is not contraindicated by the anticoagulant treatment; however, in the presence of altered coagulation tests, the insertion or removal of the catheter is not practicable.¹⁷

REGIONAL ANESTHESIA

Regional anesthesia is useful for small-to-medium-size surgical procedures; however, the oncological patient may need to be well sedated with propofol or midazolam. In pediatric patients, and patients in whom surgery of a large area is planned, however, this will not suffice, and a combined anesthesia regimen (regional and general) is recommended. Combined anesthesia enables one to use smaller amounts of intravenous analgesics and opioids than are used during general anesthesia. Moreover, the patient awakens faster and has minimal systemic side-effects.

CENTRAL BLOCKS

An epidural (cervical, thoracic, lumbar) block is accomplished by inserting a catheter into the extradural space through which local anesthetics and/or opioids are administered intermittently or continuously. This technique requires smaller quantities of opioids than the intravenous route. In addition, postoperative shivering is less than that associated with emergence of general anesthesia. This is particularly beneficial to the patient with cardiac disease.

Caudal block is particularly useful in the pediatric population, especially in very young children.¹⁸ The trans-sacral approach is an epidural block in the sacral region. The catheter/needle is inserted between the first and second or the second and third sacral vertebrae at the horizon line that joins the interfaces of the two vertebrae and the level of the posterosuperior iliac crest.

Spinal block is effective for relatively short or medium-length procedures. It requires one-tenth of the volume needed for an epidural block. When morphine is added intrathecally, postoperative pain control can last up to 24 hours.¹⁹

PERIPHERAL BLOCKS

Upper-limb blocks include several approaches that cover various anatomic areas depending on the site of surgery (Tables 35.4 and 35.5), the surgeon's preference, and the possible requirements for continuous pain control. The following paragraphs summarize general considerations regarding various blocks.

Interscalene Block

Interscalene blocks usually provide good anesthesia for procedures of the upper extremity. They are a poor choice for surgery on the medial aspect of the arm and forearm because the inferior cord, which leads to the ulnar nerve, may not be blocked.

One should be careful to avoid injecting the local anesthetic into the epidural or intrathecal space, or into the vertebral artery. Proper needle placement and careful aspiration before injection of the local anesthetic limit the incidence of such complications. The needle should be directed medially, caudally, and posteriorly.

Brachial Plexus Blocks

The interscalene, supracavicular, or infraclavicular techniques can block the brachial plexus. This habitually leads to a motor block earlier than a sensory block.

Subclavian Perivascular Brachial Plexus Block

This block provides sensorial loss identical to that offered by the subclavian block. When performing this block the anesthesiologists must bear several points in mind:

1. A puncture of the subclavian artery is common.
2. There is a risk of puncturing the lung and causing a pneumothorax. This risk can be reduced by using a short (1½-inch) needle.
3. This block may also block the stellate ganglion.
4. The phrenic nerve might be involved in the block.
5. A hematoma may occur.
6. The needle may contact the plexus before it reaches the rib.

Infraclavicular Approach of the Brachial Plexus

This approach is useful for surgery of the forearm. The roots generate the following nerves:

- | | |
|---|-------|
| 1. Lateral aspect of the musculocutaneous nerve | C5–7 |
| 2. Anteromedial aspect of the median nerve | C6–T1 |
| 3. Ulnar nerve | C8–T1 |
| 4. Posterocutaneous nerve of the forearm | C5–C8 |
| 5. Mediocutaneous nerve of the forearm | C8–T1 |

Table 35.4 Choice of blocks for upper extremity surgical procedures

	<i>Interscalene</i>	<i>Perivascular subclavian</i>	<i>Infraclavicular</i>	<i>Axillary</i>
Arthroscopy of shoulder	+			
Closed reduction dislocation of shoulder	+			
Total shoulder replacement	+			
Resection distal end clavicle	+			
Arthroplasty of shoulder for chronic dislocation	+			
Elbow surgery		+	+	+
Ulnar nerve transposition		+	+	+
Open reduction internal fixation (ORIF) olecranon		+	+	+
Procedure on fourth and fifth digits		+	+	+
Excision distal end of ulna		+	+	+
Carpal tunnel release	+	+	+	+
deQuervain's release	+	+	+	
Volar ganglion resection	+	+	+	+
Dupuytren's contracture				+
Excision ganglion dorsum wrist		+	+	
Radial collateral ligament repair	+	+	+	
Arthroplasty of thumb	+	+	+	
Open reduction internal fixation (ORIF) fracture radius	+	+	+	
Excision distal radius	+	+	+	
Procedure on digits			+	

Table 35.5 Choice of anesthesia for the upper extremity

<i>Area and nerve origin</i>	<i>Blockade approach</i>
Shoulder	
C3–4, C5–6	Interscalene
Elbow	
C5–8, T1–2	Infraclavicular
Medial aspect C8, T1–2	Subclavian perivascular
Lateral aspect	
Posterolateral aspect C5–8	
Forearm	
C5–7 Musculocutaneous nerve	Infraclavicular
C6–T1 Median nerve	Subclavian perivascular
C8–T1 Ulnar nerve	
C5–8 Posterior cutaneous nerve	
C8–T1 Medial cutaneous nerve (radial nerve) and median nerve	
Wrist and hand	
Wrist snuff box Median nerve	Subclavian perivascular
Radial nerve	
Musculocutaneous nerve	Interscalene
Hand and digits	
Ulnar and digits	Axillary
Median nerve decompression	

Surgery of the forearm region requires the blockade of all the branches originating from the brachial plexus; anatomically, the C5–8–T1 nerve roots form the latter. The block of choice of the brachial plexus can be easily achieved by the infraclavicular approach. It provides anesthesia for surgery of the forearm region because it can block all the nerves involved in this area.

Surgery at the base of the thumb requires anesthesia of the median, radial, and musculocutaneous nerves. Such anesthesia is provided by the infraclavicular approach. The latter two nerves might be missed when using the axillary approach (see below). Although the infraclavicular, interscalen, and subclavian perivascular approaches to the brachial plexus block are equally good techniques for surgery at the base of the thumb, the infraclavicular approach is particularly beneficial when used in a continuous mode by the insertion of an epidural catheter.

Axillary Approach to the Brachial Plexus Block

For this block the patient must adduct the arm by 90°. This may pose a problem in patients with limited shoulder motion (e.g. individuals whose shoulder is affected by rheumatoid arthritis). This block provides good anesthesia for surgery on the hand and wrist, especially in the area of the ulnar nerve distribution. It may not provide good anesthesia to the area supplied by the radial nerve in the lateral aspect of the hand and forearm. This approach also may not block the musculocutaneous nerve, which innervates the snuffbox. Another limitation of this block is that it usually does not provide anesthesia to the region above the elbow, even though it may be effective at the elbow itself. The brachial plexus block achieved by the axillary technique provides a greater sensory block and a poorer motor block than the other earlier-described approaches.

Surgical procedures at the wrist and the hand which may be done under an axillary block include median nerve decompression (carpal tunnel syndrome), excision of ganglia tendon, nerve repair, and reduction/fixation of small fractures.

Humeral Canal Nerve Block

Patients who are unable to abduct an arm, and who need a block of the brachial plexus at the arm and wrist distribution, may benefit from a humeral canal nerve block. This block is useful for all interventions done under the axillary block approach, and it anesthetizes that region to some degree. The needle is introduced next to the brachial artery at the mid-length of the arm, and the various nerves (ulnar, median, and radial) are identified with a nerve stimulator.

Block of the Lower Limb: its Nerves and Dermatomes

Psoas Block

The psoas (paravertebral) block is an efficient way to treat chronic pain of the lower limb. It is also useful perioperatively, because continuous pain control can be achieved by the administration of local anesthetics (with or without opioids) via a continuous epidural catheter. The lumbar plexus is formed by the ventral rami of the first, second, third, and major parts of the fourth lumbar nerves. It is located deep in the psoas major muscle, in a kind of compartment formed by the muscle and its fascia anteriorly; the bodies of the lumbar vertebrae medially; and the transverse process of the same vertebrae, the intertransverse ligaments and muscles, and the quadratus lumborum muscle posteriorly.

A group of nerves innervating the upper segment of the lower limb lies in close proximity to the line between the fourth and fifth lumbar vertebral transverse processes. They run from laterally to medially and include the lateral-cutaneous nerve of the thigh, the femoral nerve, the genitofemoral nerve, the obturator, and the lumbosacral trunk. In orthopedic oncology patients the psoas block is mainly used for hip prosthesis, total hip replacement, patellectomy, leg amputation (above- or below-knee), tibial plating, and operation on the toes, including ankle open reduction and internal fixation (ORIF).

Three-in-one Block

This distinctive block was first postulated by Winnie and applied by Lonsdale.²⁰ It consists of administering an abundant volume of local anesthetic below the fascia iliaca in order to block all nerves composing the lumbar plexus. The application of this block requires that one draws an imaginary line between the anterosuperior iliac crest and the symphysis pubis point. At one-third of the distance between the iliac crest downward and 1 cm below the line, the needle is introduced at a 90° angle to the skin. The femoral nerve can be blocked completely, but there is only a 90% success of anesthetizing the laterofemoral cutaneous nerve and a 75% success in the obturator nerve. The lumbar plexus is entirely blocked only in about 60% of the patients, especially the genitofemoral ramus.

The femoral nerve block is effective for femoral bone surgery or biopsy in the anterior region of the lower limb. It is the most important and extensive peripheral nerve block of the lower limb, especially when combined with the psoas block. In such occasions the neural and muscle masses are completely anesthetized.

Sciatic Block

The sciatic nerve originates from L4–5, S1–3 roots. It innervates the posterior part of the thigh and all areas below the knee joint except the medial aspect up to the medial malleolus, which is supplied by the saphenous nerve. The sciatic block affects the sensory part of the sciatic nerve and its rami and allows operating only on the foot.²¹ More extensive operations require additional nerve blocks, such as a femoral or an obturator nerve block. The sciatic block is frequently used to obtain perioperative analgesia. There are three different approaches to this block: anterior, posterior, and lateral. Each is easy to perform and is almost always successful. To apply this block the patient is placed on the bed in the Sims position on the side opposite to the one to be blocked. The hip and knee are flexed, and the knee on the side to be blocked should cross over the body and touch the bed.

The block landmark is the line between the posterosuperior iliac crests and the greater trochanter.

Distal Block of the Lower Limb

The distal block is useful when preparing for a small-size procedure or when the patient is fragile and general anesthesia is unacceptable.

PHANTOM LIMB PAIN AND SENSATION

Ambroise Pare first described phantom limb pain after Lord Nelson had lost his arm at the Tenerife battle in 1797. The patient immediately or some time after the limb amputation can feel both sensation and pain. The authors refer to both symptoms as “phantom pain”; for information regarding the distinction between the two, see Hord’s review.²² None of the theories attempting to explain the phantom phenomena has been entirely satisfactory. Most researchers suggest that this kind of pain arises in the residual parts of the peripheral sensory neuron;²³ others contend that it originates from within the central nervous system.²⁴ It may also be a product of a neuropsychological process representing a sort of unconsummated mourning for the lost body part.²⁵

Phantom pain may appear spontaneously; however, in most cases a local or remote stimulus triggers it. The pain may appear immediately after amputation, but there is habitually a short period of latency. Psychological or visceral stress (e.g. urination or defecation) can also give origin to such pain. The intensity of phantom pain is directly proportionate to the severity and duration of pain endurance before the amputation or the degree of perioperative-related psychological distress.²⁶ Although the severity of pain usually

decreases over a period of years, it may reappear after years of absence.

Conservative treatment such as the classic analgesics (e.g. paracetamol, nonsteroidal anti-inflammatory drugs, propoxyphene, or even morphine) are generally ineffective to control phantom pain, and their prolonged use may bear many side effects. These drugs are coadjuvated with tricyclic antidepressants (e.g. amitriptyllin), anticonvulsives (e.g. depakin), neuroleptics (e.g. halidol). The concomitant perineural injection of local anesthetics such as of lidocaine, the use of transcutaneous electrical nerve stimulation, or ultrasound are also options for phantom pain control. Regional analgesia (e.g. epidural block) is another alternative. Finally, psychological treatment, relaxation, biofeedback, hypnosis, and various complementary methods such as auriculotherapy and acupuncture are acceptable tools.^{24,27}

Several institutions also use invasive methods of pain control in these patients. These include spinal cord stimulation and the interruption of the nerves from the periphery to the cortex. Surgery is used only for treating highly resistant phantom pain.²⁸

PERINEURAL ANESTHESIA

Perineural anesthesia is effective in controlling post-operative pain and reducing narcotic requirements following limb-sparing resection or amputation. In our experience it has also been effective in preventing phantom limb pain. It can be utilized in all anatomic locations. During limb-sparing resection or amputation all major neurovascular bundles are routinely exposed; thus they are easily amenable to perineural anesthesia. During surgery, prior to wound closure, each major nerve sheath is opened using a blunt right-angled clamp. A 20-gauge Silastic epineural catheter is threaded proximally at least 5 cm in the nerve sheath. The sheath opening is closed around the catheter using a 4-0 absorbable suture, being sure to anchor the catheter securely. This is performed for each major nerve that has been exposed during the surgical procedure. Catheters are externalized through separate stab wounds made in the skin with a 16-gauge angiocath and stitched in place. Following limb-sparing resection the patient is awakened from anesthesia, and neural integrity is checked in the operating room. Immediately following a baseline neurological examination, a 10–20 ml bolus of 0.25% bupivacaine is delivered into each catheter. For amputees the bolus is given prior to awakening from anesthesia, since good perioperative pain control is believed to prevent phantom limb pain. The catheters are attached to standard intravenous infusion pumps and the rate is

set at 4 ml/h of 0.25% bupivacaine. This rate can be titrated for optimal pain relief. Catheters are typically left in place for 5–7 days. Some amputees, particularly those with intense and prolonged preoperative pain, are prone to pain-management problems. In these instances perineural anesthesia can be continued as an outpatient using portable infusion pumps, until pain can be adequately controlled with oral medications. **Table 35.6** is a summary of the major nerves exposed and used for perineural anesthesia following limb-sparing resection and amputations.

Several centers have been utilizing perineural anesthesia for all limb-sparing resections and amputations. The procedure is safe and reliable, although there is some risk of systemic toxicity. Typically, adults require 120–240 mg of bupivacaine 0.25% over a 24-h period. Perineural anesthesia can reduce postoperative pain by 90–95% and thus reduce narcotic requirements drastically (~80% reduction).

POSTOPERATIVE ANALGESIA

Maintaining an acute pain-control service requires dedication from the members of the pain management team. They must be available day and night, and respond promptly to any kind of request or call from the nurse, surgeon, patient, or family. Every hospital that treats cancer patients should have a team whose responsibility is to operate the pain-control service. This group includes anesthesiologists and intensivists, surgeons, nurses, psychologists, social workers, and volunteers. All patients having pain problems are introduced to the team. With the attending physician they select the best protocol for the specific patient. Although this decision is made independently from the type of surgery, it must take it into account.²⁹

A successful postoperative pain treatment depends on several factors. First, the surgical team must discuss the plan in detail with the selected family members who must be trained to carry out the plan. The family must comply with the pain-control plan and believe it will serve the patient optimally. Second, an objective person such as an attending nurse must perform pain assessment frequently during the immediate postoperative period. Third, the patient must report his or her pain objectively, without exaggerating or underevaluating its severity. Any side-effects must also be reported. Side-effects may be the first sign of a need to

Table 35.6 Major nerves exposed and used for perineural anesthesia

	<i>Nerves Utilized</i>
<i>Limb-sparing resection</i>	
Proximal femur	Sciatic and femoral nerves
Caution: avoid vascular pedicle to gluteus maximus in greater sciatic notch	
Distal femur	Sciatic nerve
Proximal tibia	Sciatic nerve
Proximal humerus	Brachial plexus
<i>Amputation</i>	
Hemipelvectomy	Iliolumbar and femoral nerves
Hip disarticulation	Sciatic, femoral, and obturator nerves
Above-knee amputation	Sciatic nerve and percutaneous femoral nerve (placed lateral to the femoral pulse)
Forequarter amputation	Brachial plexus

discontinue the mode of treatment, change the dosage, or switch to a different drug. The nurse must regularly record the patient's vital signs (i.e. heart rate, blood pressure, respiratory rate and oxygen pulse oximetry) and ensure they remain within acceptable limits in the specific patient. The nurse and the entire team should be prepared to take measures to stop pain treatment when necessary, as well as to initiate resuscitation measures and call for help in emergencies.

It is essential to prescribe the exact dosage and indicate the mode of administration of each drug, as well as to calculate the dose accurately. The oncological patient usually requires a series of repeated procedures following surgery. The aim of a pain-control modality is to attenuate, or even abolish, the pain associated with the treatment. The more compliant the patient is with the pain-control system, and the more appropriate the dosing and type of drug, the stronger the patient will be in undergoing additional therapeutic protocols.

References

- Mihalo RM, Cagle CK, Cronau LH Jr *et al.* Preanesthetic evaluation of the cancer patient. *Cancer Bul.* 1995;47:8–12.
- Zaloga PZ, Prough DS. Fluids and Electrolytes. In: Barash PG, Cullen BF, Stoelting RK, editors. *Clinical Anesthesia*, 2nd edn. Philadelphia, PA: JB Lippincott; 1992:203–36.
- American Society of Anesthesiologists Task Force on Pain Management. Cancer Pain Section: Practice guidelines for cancer pain management. *Anesthesiology.* 1996;84:1243–57.
- Bolles RC, Fanselow MA. Perceptual defensive–recuperative model of fear and pain. *Behav Brain Sci.* 1980;3:291–323.
- Jones RM. Desflurane and sevoflurane: inhalation anaesthetics for this decade? *Br J Anaesth.* 1990;65:527–36.
- Jones RM. Anaesthetic considerations in patients with malignancy. In: Keneally JP, Jones MR, editors. *Proceedings of the 11th world Congress of Anaesthesiologists*, April 1996, Sydney, Australia. Rosebery, UK: Bridge Printery Pty Ltd; 1996:212–21.
- Bountra C, Gale JD, Gardner CJ *et al.* Towards understanding the aetiology and pathophysiology of the emetic reflex: novel approaches to antiemetic drugs. *Oncology.* 1996;53(Suppl. 1):102–9.
- Heslin MJ, Gaynor JJ, Newman E *et al.* Effect of perioperative blood transfusion on recurrence and survival in 232 primary high-grade extremity sarcoma patients. *Ann Surg Oncol.* 1994;1:189–97.
- Hudson RJ. Basic principles of clinical pharmacology. In: Barash PG, Cullen BF, Stoelting RK, editors. *Clinical Anesthesia* 3rd edn. Philadelphia, PA: Lippincott – Raven; 1997:221–42.
- Monk CR, Coates DP, Prys-Roberts C *et al.* Haemodynamic effects of a prolonged infusion of propofol as a supplement to nitrous oxide anaesthesia. *Br J Anaesth.* 1987;59:954–60.
- Reves JG, Fragen RJ, Vinik HR, Greenblatt DJ. Midazolam: pharmacology and uses. *Anesthesiology.* 1985;62:310–24.
- Hobbhahn J, Funk W. Sevoflurane in pediatric anesthesia. *Anaesthetist.* 1996;45(Suppl. 1):S22–7.
- Davis PJ, Cohen IT, McGowan FX, Jr, Latta K. Recovery characteristics of desflurane versus halothane for maintenance of anesthesia in pediatric ambulatory patients. *Anesthesiology.* 1994;80:298–302.
- Flacke JW, Bloor BC, Kripe BJ *et al.* Comparison of morphine, meperidine, fentanyl and sufentanyl in balanced anesthesia: a double-blind study. *Anesth Analg.* 1985;64:897–910.
- Flordal PA, Bergqvist D, Burmark US *et al.* Risk factors for major thromboembolism and bleeding tendency after elective general surgical operations. The Fragmin Multicentre Study Group. *Eur J Surg.* 1996;162:783–89.
- Dunn CJ, Sorkin EM. Dalteparin sodium. A review of its pharmacology and clinical use in the prevention of thromboembolic disorders. *Drugs.* 1996;52:276–305.
- Vandermeulen EP, Van Aken H, Vermeylen J. Anticoagulants and spinal-epidural anesthesia. *Anesth Analg.* 1994;79:1165–77.
- Yaster M, Maxwell LG. Pediatric regional anesthesia. *Anesthesiology.* 1989;67:324–38.
- Wang JK, Nauss LA, Thomas JE. Pain relief by intrathecally applied morphine in man. *Anesthesiology.* 1979;50:149–51.
- Lonsdale M. 3-in-1 block: confirmation of Winnie’s anatomical hypothesis. *Anesth Analg.* 1988;67:601–2.
- Chang PC, Lang SA, Yip RW. Reevaluation of the sciatic nerve block. *Reg Anesth.* 1993;18:18–23.
- Hord AH. Phantom pain. In: Raj PP, editor. *Practical Management of Pain*. 2nd edn. St Louis, MO: Mosby Year Book; 1992:505–16.
- Devor M. The pathophysiology of damaged peripheral nerves. In: Wall PD, Melzack R, editors. *Textbook of Pain*, 3rd edn. London: Churchill–Livingstone; 1994:79–100.
- Melzack R. Phantom limbs. *Sci Am.* 1992;266:120–6.
- Katz J, Melzack R. Pain “memories” in phantom limbs. Review and clinical observations. *Pain.* 1990;43:319–36.
- Bach S, Norang ME, Tjellden NU. Phantom limb pain in amputees during the first twelve months following limb amputation, after preoperative lumbar epidural blockade. *Pain.* 1988;33:297–301.
- Monga TN, Jaksic T. Acupuncture in phantom limb pain. *Arch Phys Med Rehabil.* 1981;32:229–31.
- Miles J. Surgical procedures for the relief of pain. *Pharmacol Ther.* 1983;12(Suppl.):89–98.
- Warfield CA, Kahn CH. Acute pain management. Programs in US hospitals and experiences and attitudes among US adults. *Anesthesiology.* 1995;83:1090–4.

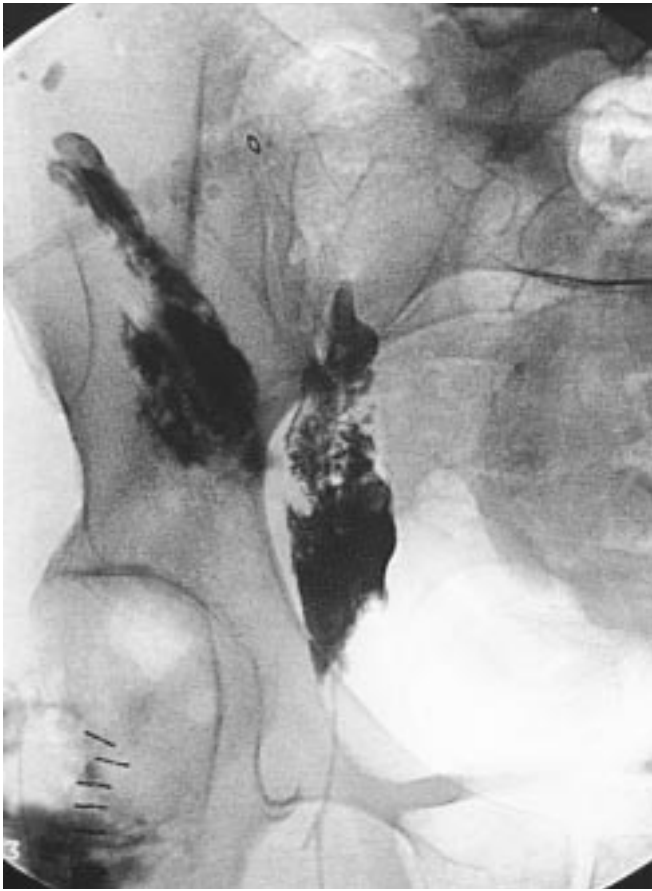


Figure 35.1 Epineural injection following hip disarticulation. Contrast media indicates position of the catheter in the obturator nerve sheath and sciatic nerve.

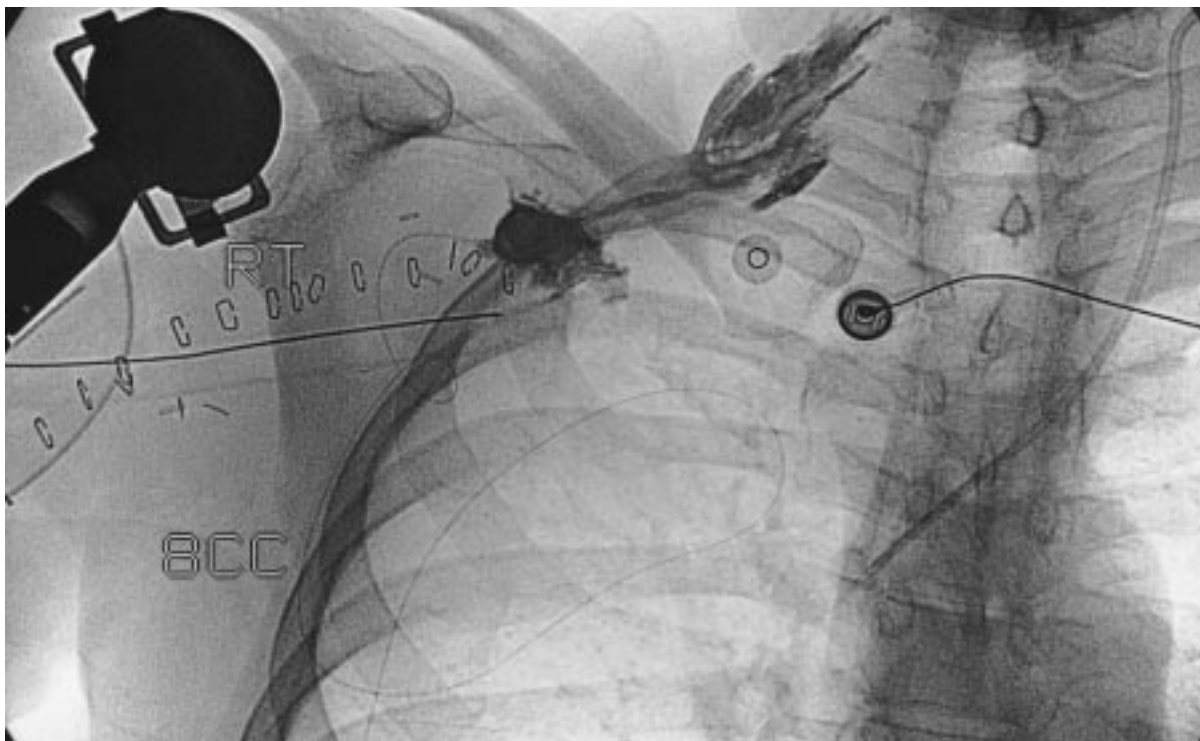


Figure 35.2 Epineural catheter with contrast media in the proximal brachial plexus, following a proximal humeral resection.

